

SCIENTIFIC  
JOURNAL

# BEYOND Full Arch



# BEYOND Full Arch SCIENTIFIC JOURNAL

## AUTHORS:

### **DRA. BRUNA GHIRALDINI**

PhD in Implant Dentistry – Universidade Paulista.  
MBA in Business Management – Fundação Getúlio Vargas. Master's Degree in Periodontics – Universidade Paulista. Specialist in Periodontics – Universidade Paulista. Postgraduate in Implant Dentistry – INEPO. Postgraduate in Aesthetics – SOESP. Coordinator of the Product Research and Development Department – S.I.N.

### **DR. BRENNO MARCONDES NEGRI**

Professor and Clinical Coordinator of the Specialization Course in Implant Dentistry at ADOB - Riberão Preto, Master's Student in Implant Dentistry at São Leopoldo Mandic - SP, Specialist in Implant Dentistry at UNIP - SP, Specialist in Public and Family Health Dentistry at Unyleya - SP, Graduate of FO-USP - SP, National Specialist in the Product Research and Development Department – S.I.N.

### **DR. UMBERTO RAMOS DEMONER**

Degree in Dentistry from the Federal University of Espírito Santo; Specialization, Master's, and PhD in Periodontics from FORP-USP; Sandwich PhD conducted at Augusta University; Visiting Researcher at the Adams School of Dentistry at the University of North Carolina; International Specialist in the Product Research and Development Department – S.I.N.

# SUMMARY

**04** ● EDITORIAL

**05** ● HISTORY AND DEVELOPMENT

**06** ● SCIENTIFIC JOURNAL

**11** ● CLINICAL CASES

12 Beyond Full Arch Immediate Load Rehabilitation,  
by Dr. Pablo Enrico Monteiro Martins and Dr. Fábio Luis Bunemer Guerra

18 Rehabilitations of Atrophic Maxillae: Epikut Plus, Epikut Long Plus, and  
Epikut S PTG Plus Implants,  
by Dr. Matheus Teixeira

23 Epikut Long in the Treatment of Severely Atrophic Maxilla,  
by Dr. Maiolino Thomaz Fonseca Oliveira

29 Zygomatic Plus,  
by the Teaching and Research Center in Implant Dentistry team at UFF/RJ

34 Total Maxilla Rehabilitation with Conventional, Zygomatic, and Pterygoid Implants,  
by Dr. Guilherme Amaral

# EDITORIAL

**DR. UMBERTO DEMONER RAMOS**

---

PhD in Periodontics and Scientific Consultant at S.I.N.

Imagine an 80-year-old woman, Aláide, who has been using a complete upper denture for 35 years, walking into your clinic seeking fixed teeth. This woman, understandably, presents with extensive bone resorption, which makes even a typical protocol with four implants the minimum number of implants for the maximum number of teeth unfeasible. You examine the CT scan and conclude that she would need a sinus lift, and possibly extensive bone grafting to achieve horizontal bone gain. You present the treatment plan: at least 12 months before the actual rehabilitation can begin. She will be at least 81 years old by the time the treatment is completed five years older than the average life expectancy of a Brazilian born today. You would agree that, for this lady, 9 to 12 months is a long time, and the ideal would be for her to have functional and aesthetic “new teeth” as soon as possible. It’s a matter of fixing the teeth and time.

For this reason, we, oral health professionals, in our mission to create new smiles and rehabilitate people who, for whatever reason, have suffered oral mutilation, must offer treatment options that can recover this lost time. And for that, we must go beyond we cannot limit ourselves to just one option. Even if you are “team regeneration,” you would agree that Mrs. Aláide is in a hurry.

To solve both problems fixed teeth and time we need to seek techniques that go beyond the obvious, beyond the limited maxillary bone that many patients, like Mrs. Aláide, present with. We need what is called remote anchorage: implants anchored in high-quality bone, extra-maxillary, such as the nasal, zygomatic, and pterygoid bones. For that, we also need implants that go beyond the usual beyond what we use in single cases and even full-arch protocols in younger patients with more available bone. We need special implants, long implants designed with primary stability in mind.

Upon graduation, we took the famous Hippocratic Oath, in which we committed to offering treatments that prioritize the health and well-being of our patients, as well as to practicing our profession according to best practices. One way to honor these two lines of our oath is to offer treatment options that are grounded in high-quality science. This magazine presents clinical solutions for evidence-based practice, so that patients like Mrs. Aláide, my grandmother, can be rehabilitated with safety, predictability, and, ultimately, quality.

# HISTORY & DEVELOPMENT

Thinking beyond the basics, S.I.N. strives to innovate its products to support full-arch immediate loading rehabilitations, always grounded in science. To achieve this, before any launch, a whole team of engineers, dentists, and opinion leaders work together with the goal of designing and producing solutions that will significantly change the clinical daily routine of implantologists, periodontists, and prosthodontists. To this end, an entire line of remote anchorage systems, aimed at “full arch” rehabilitations, has been developed.

Obviously, the entire development process involves not only gathering opinions and seeking convergence in rehabilitation philosophy but also rigorous scientific work. This includes preclinical animal studies, when necessary, following ARRIVE and CONCEA guidelines, as well as computational finite element analyses to anticipate potential issues in various clinical implant situations. This is complemented by strict internal and external mechanical tests to assess the mechanical strength of the implant-component assembly and, of course, clinical validations that ensure the conceived design truly meets the needs and premises for which it was created.

Basically, if something does not withstand enough stress, it will not be brought to market. If something is not good enough for clinical use, it will not reach the market. After all, at the end of the day, we rehabilitate people, not just mouths, and patient safety comes first.

The Beyond Full Arch line aims to go beyond the obvious and was designed for dentists seeking high insertion torque with predictability to achieve immediate loading in their rehabilitations, without altering their prosthetic connection and without the need to stock multiple components.

With implants ranging from regular sizes, such as the Epikut S, to long implants like the Epikut S Long, and even special implants like the Zygomatic Plus and Epikut S PTG Plus, each is developed for specific uses, tested and approved by our development dentists and ambassadors, combining market needs with scientific foundation.

Regardless of the philosophy for or against zygomatic implants, or for or against implants anchored in the nasal bone or even pterygoid implants, the Beyond Full Arch line provides the clinician with something important when offering rehabilitation to their patient: choice.



# SCIENTIFIC ARTICLES

# THE IMPACT OF BIOACTIVE SURFACES IN THE INITIAL STAGES OF OSSEOINTEGRATION: A COMPARATIVE IN VITRO STUDY EVALUATING THE HYDROPHILIC SURFACES HANANO® AND SLACTIVE®

BIOMED RESEARCH INTERNATIONAL

Rodrigo A. da Silva<sup>1,2,3</sup>, Geórgia da Silva Feltran<sup>1</sup>, Marcel Rodrigues Ferreira<sup>1</sup>, Patrícia Fretes Wood<sup>1</sup>, Fabio Bezerra<sup>1</sup> and Willian F. Zambuzzi;

<sup>1</sup> Lab. of Bioassays and Cellular Dynamics, Department of Chemical and Biological Sciences, Institute of Biosciences, UNESP-São Paulo State University, 18618-970, Botucatu, São Paulo, Brazil;

<sup>2</sup> School of Dentistry, University of Taubaté, 12020-340, Taubaté, São Paulo, Brazil;

<sup>3</sup> Program in Environmental and Experimental Pathology, Paulista University, São Paulo, 04026-002 São Paulo, Brazil.

There is a growing effort to develop active and innovative surfaces aimed at accelerating osseointegration, such as the nanosized crystalline hydroxyapatite coating (HANano®). To better understand the biological behavior of osteoblasts cultured on the HANano® surface, the data were compared with SLActive®, a titanium surface treated with sandblasting. Methodologically, osteoblasts were cultured on both surfaces for up to 72 hours to assess cell adhesion, viability, and the set of genes encoding proteins related to adhesion, proliferation, and differentiation. Our data show that HANano® provides an interesting substrate to support cell adhesion with cells exhibiting typically spread morphology, whereas cells adhered to SLActive® display a spindle-shaped morphology. Our data indicate that the cell adhesion mechanism was accompanied by the upstream expression of integrin  $\alpha 1$ , Fak, and Src,

favoring the assembly of focal adhesion platforms and coupling with cell cycle progression (upregulation of the genes Cdk2, Cdk4, and Cdk6) in response to HANano®. Additionally, both bioactive surfaces promoted osteoblastic differentiation stimulation through activation of the genes Runx2, Osterix, and Alp. Although both surfaces promoted the expression of the Rankl genes, the expression of the Opg genes was higher in SLActive®, and this difference was reflected in the Rankl/Opg ratio. Finally, the Caspase-1 gene was significantly upregulated in response to HANano®, suggesting involvement of the inflammasome complex. This study, as a whole, provides sufficient evidence to confirm that the nanosized hydroxyapatite-coated surface provides the necessary microenvironment to enhance osteoblast performance in dental implants and predicts that these osteogenesis phases occur during the initial stages of osseointegration.



**FULL ARTICLE**

## NEW CONCEPT OF IMPLANTS FOR HIGH PRIMARY STABILITY IN LOW-DENSITY BONE AND POST-EXTRACTION SOCKETS

IMPLANTNEWS – ORAL REHABILITATION FROM A TO Z

Nelson R. F. A. Silva<sup>1</sup>, Felipe Moura Araújo<sup>2</sup>, Roberto Sales e Pessoa<sup>3</sup>, Mônica Diuana Calasans-Maia<sup>4</sup>, Bruna Ghiraldini<sup>5</sup>, Fábio J. B. Bezerra<sup>6</sup>;

<sup>1</sup>Mestre e doutor em Prótese – FOB-USP; Pós-doutor em Biomateriais – NYU; Professor associado do Depto. de Odontologia Restauradora – Faculdade de Odontologia da UFMG. Orcid: 0000-0002-9876-6017;

<sup>2</sup>Doutorando em Implantodontia – Universidade de Guarulhos; Coordenador do curso de especialização em Implantodontia – ABO/SP e ETEC/MG. Orcid: 0000-0001-6160-9512;

<sup>3</sup>Doutor em Periodontia e Implantodontia – FOAr/Unesp; Professor do Depto. de Periodontia e Implantodontia – Universidade do Triângulo Mineiro. Orcid: 0000-0003-1763-3691;

<sup>4</sup>Especialista e mestra em CTBMF – UFRJ; Doutora em Patologia e professora titular do Depto. de Cirurgia Oral Menor – Universidade Federal Fluminense. Orcid: 0000-0001-5759-7926;

<sup>5</sup>Doutora em Implantodontia – Unip; Coordenadora do Depto. de Pesquisa e Desenvolvimento – S.I.N. Implant System. Orcid: 0000-0002-3693-3035;

<sup>6</sup>Doutor em Biotecnologia – Instituto de Biociências/Unesp; Diretor do Depto. de Pesquisa e Desenvolvimento – S.I.N. Implant System. Orcid: 0000-0003-0330-2701.

**Objective:** This article presents a new implant proposal with specific characteristics for challenging clinical situations.

**Materials and Methods:** All implants were placed by professionals with a minimum of ten years of prior experience, following the manufacturer's recommendations,

a form containing information about the patients' sex and age, the type of implant installed, the type of socket (fresh or healed), the use or not of simultaneous bone grafting, trans- and post-operative complications, clinical or radiographic changes, and osseointegration success was used for data collection. Two representative cases were photographed and presented..

**Results:** In total, 161 implants (109 CM and 52 HE; diameters: 3.5 mm to 4.5 mm, lengths: 10 to 13 mm) were installed in 91 patients (68% men, 32% women, with an average age of 50 years). Of these, 65% of the implants were placed in post-extraction sockets, and 53% were associated with intra-alveolar grafts. The average insertion torque was 45 N.cm, enabling immediate loading when clinically indicated. The overall survival rate was 99.37%.

**Conclusion:** Within the limitations of this study, the cases presented suggest the effectiveness of the new implant design for situations involving low bone density or when immediate loading is indicated.

# THE INFLUENCE OF THE NANOSTRUCTURED HYDROXYAPATITE SURFACE ON THE INITIAL STAGES OF OSSEOINTEGRATION: A MULTIPARAMETRIC STUDY IN LOW-DENSITY BONE IN ANIMALS

INTERNATIONAL JOURNAL OF NANOMEDICINE

Suelen Cristina Sartoretto<sup>1,2</sup>, Jose de Albuquerque Calasans-Maia<sup>3</sup>, Rodrigo Figueiredo de Brito Resende<sup>4</sup>, Eduardo Câmara<sup>2</sup>, Bruna Ghiraldini<sup>5</sup>, Fabio José Barbosa Bezerra<sup>6</sup>, Jose Mauro Granjeiro<sup>7,8</sup>, Monica Diuana Calasans-Maia<sup>4</sup>;

<sup>1</sup>Oral Surgery Department, Universidade Veiga de Almeida, Rio de Janeiro, RJ, Brazil; Oral Surgery Department, Universidade Iguçu, Nova Iguçu, RJ, Brazil;

<sup>2</sup>Post-Graduation Program in Dentistry, Universidade Veiga de Almeida, Rio de Janeiro, RJ, Brazil;

<sup>3</sup>Orthodontics Department, Dentistry School, Universidade Federal Fluminense, Niteroi, RJ, Brazil;

<sup>4</sup>Oral Surgery Department, Universidade Federal Fluminense, Niteroi, RJ, Brazil;

<sup>5</sup>Dental research Division, Dentistry School, Universidade Paulista, São Paulo, SP, Brazil; <sup>6</sup>Laboratory of Bioassays and Cell Dynamics, IBB-UNESP, Botucatu, Brazil.

Dental implants in partially or fully edentulous patients are a predictable treatment with high long-term success rates<sup>1</sup>. However, early osseointegration is still considered a challenge in areas with more trabecular bone (type IV bone)<sup>2</sup>, along with thinner and less dense cortical bone, which is generally regarded as less suitable for supporting dental implants.

In recent years, new implant surface technologies with micro- to nanotopography, new chemical compositions, new loading protocols, and new surgical techniques have been introduced to improve osseointegration and reduce treatment time, allowing for immediate or early functional loading in patients with reduced bone density.<sup>3-5</sup>

Various approaches to improve dental implant surfaces have been studied, including mechanical, chemical, and physical techniques<sup>6</sup>. Calcium phosphate has been widely used as a bone substitute<sup>7, 8</sup>; dental implant coating<sup>9</sup>; and carrier of proteins<sup>10</sup>, growth factors<sup>1</sup>, and

antimicrobials<sup>12-14</sup> due to its similarity to the mineral fraction mineral of bone tissue and its adequate capacity for cell adhesion. Among calcium phosphates, hydroxyapatite, in particular, has been favored due to its biocompatibility, safety, predictability, unlimited availability, lower patient morbidity, and cost-effectiveness, offering significant advantages and making it a good choice for dental implant surface coatings.<sup>15</sup>

The use of nanostructured hydroxyapatite to coat titanium implant surfaces increases the strength of the bond between titanium and bone, enhances the rate of osseointegration, and reduces the duration of the treatment period, especially in patients with poor bone quality.<sup>9</sup>

There is a continuous increase in research focused on developing new bioactive surfaces to reduce the osseointegration period in low-density bone. This study aimed to compare the bone response of the surface coated with HAnano® (S.I.N., São Paulo, Brazil) with well-known hydrophilic surfaces such as SLActive® (Straumann, Basel, Switzerland) and TiUnite® (Nobel Biocare, Gothenburg, Sweden) through histomorphometric analysis of bone-implant contact (BIC) and bone area fraction occupancy (BAFO) in a low-density ovine iliac crest model.



FULL ARTICLE



# CLINICAL CASES

# BEYOND FULL ARCH IMMEDIATE LOADING REHABILITATION



BY DR. PABLO ENRICO MONTEIRO MARTINS  
AND DR. FÁBIO LUIS BUNEMER GUERRA

**Dr. Pablo Enrico Monteiro Martins** - Specialist in Implant Dentistry / Dental Prosthetics. Master's Student in Implant Dentistry

**Dr. Fábio Luis Bunemer Guerra** - Specialist in Oral and Maxillofacial Surgery / Implant Dentistry. Master in Implant Dentistry

## CASE INTRODUCTION

Female patient, 60 years old, presenting with a completely edentulous maxilla and significant bone resorption, especially in the posterior regions. She had been using a complete upper denture for several years and reported functional discomfort, prosthetic instability, and a negative impact on her quality of life. Given the patient's desire for a fixed, predictable, and definitive solution, a treatment plan using Beyond Full Arch with immediate loading was proposed, aiming to restore masticatory function, aesthetics, and comfort.

## TREATMENT EXPLANATION

The surgical-prosthetic planning followed the principles of Beyond Full Arch rehabilitation with immediate loading, aiming for adequate primary stability and support for a fixed upper prosthesis. Four conventional implants (Epikut model, S.I.N.) were placed in the regions of teeth 13, 12, 21, and 22, respecting axial alignment and functional distribution.

To compensate for the posterior bone atrophy and obtain additional anchorage, two Zygomatic Plus implants were placed in the regions of teeth 15 and 24. Epikut S PTG Plus implants were also inserted in regions 18 and 28, with excellent primary stability. However, it was decided not to use these in the final prosthetic rehabilitation, since the conventional implants and Zygomatic Plus already provided sufficient anchorage for the installation of the protocol-type prosthesis. The result was a fixed, stable, and functional prosthetic structure, respecting the aesthetic and biomechanical parameters of the arch.

## PATIENT RECORD

**Patient:** 60 years old, female.

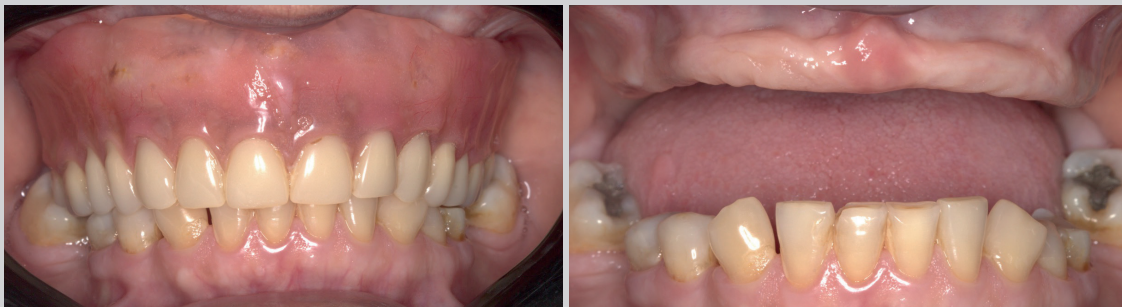**Complaint:** Functional discomfort, prosthetic instability, and negative impact on quality of life.

**Medical History:** Edentulous and atrophic maxilla; user of a complete upper denture.

**Treatment Plan:** Fixed maxillary rehabilitation using full arch with immediate loading.

## BEFORE

During the initial phase of treatment, photographs of the patient were taken while using her conventional complete upper denture. These images were used to document the pre-treatment condition and to ensure effective communication with the prosthetics laboratory, making sure that the patient's aesthetic and functional expectations were well understood. In addition, an initial impression was taken to obtain accurate models of the dental arches. Based on these models, a multifunctional guide was fabricated, essential for reestablishing the patient's proper Vertical Dimension of Occlusion (VDO). This guide incorporated the selected teeth for the final prosthesis, allowing the patient to preview the expected treatment outcome, providing a realistic preview aligned with her expectations.



## X-RAY/CT SCAN

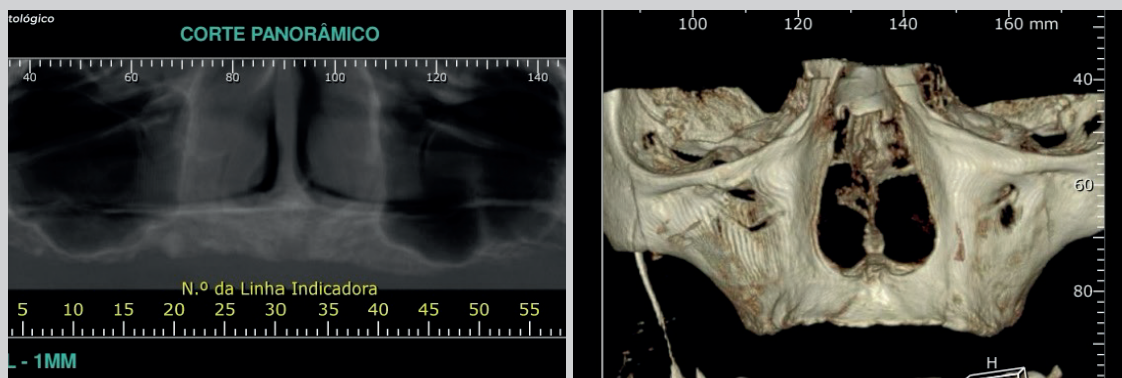
The CT scan revealed significant bone atrophy, especially in the posterior regions of the maxilla, limiting the use of conventional implants in those areas. Given this scenario, we opted for a combined approach using different types of implants to maximize stability and load distribution:

**Anterior region:** Epikut implants, whose macrogeometry provides high primary stability, ideal for areas with lower bone density.

**Premolar region:** Zygomatic Plus implants, which allow anchorage in the zygomatic bone, offering an effective solution for atrophic maxillae without the need for bone grafts.

**Molar region:** Epikut S PTG Plus implants, anchored in the pterygoid plate of the sphenoid bone, providing additional support in the posterior maxilla.

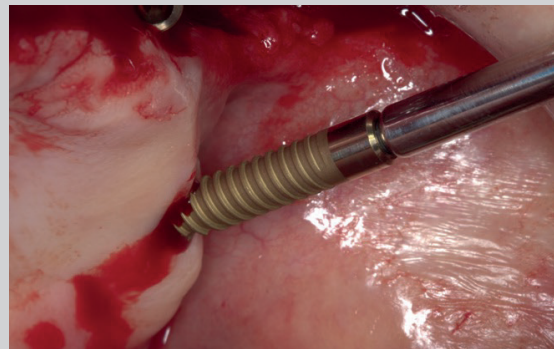
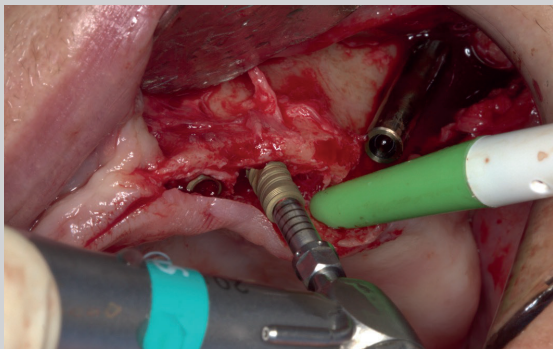
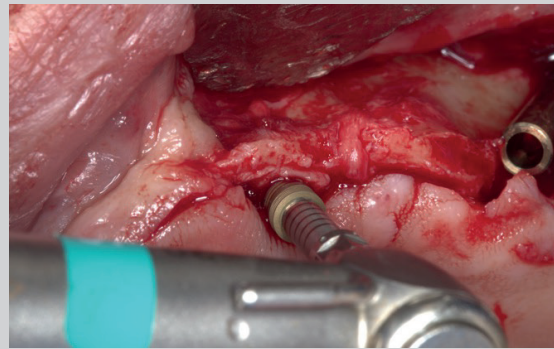
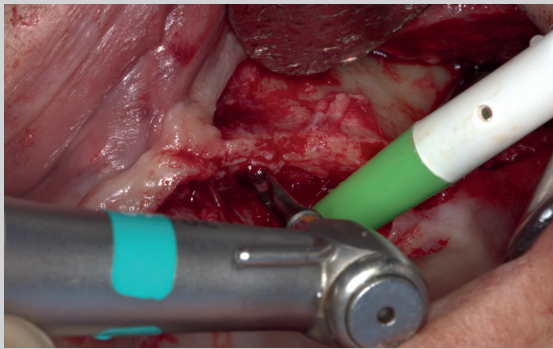
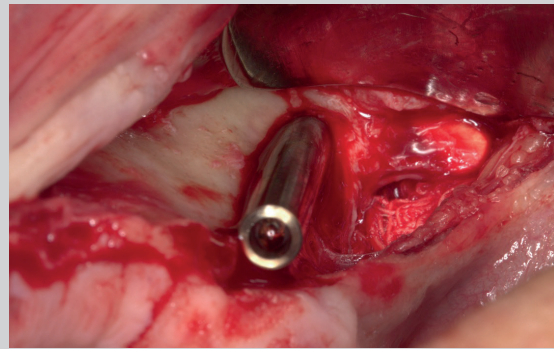
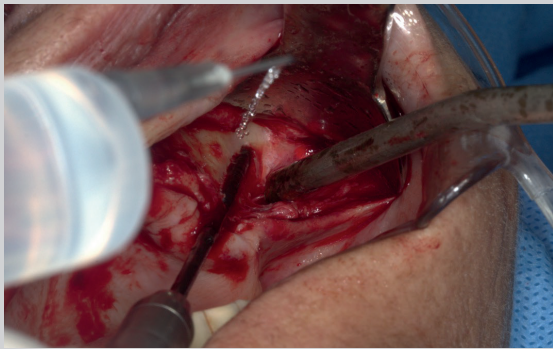
This integrated strategy enabled the execution of a Beyond Full Arch rehabilitation with immediate loading, effectively meeting the patient's functional and aesthetic needs.



## INTRAOPERATIVE

The surgical procedure was performed under local intraoral and extraoral anesthesia, ensuring comfort and adequate pain control throughout the intervention. The surgical approach was carried out by hemimaxilla, starting with the left side.

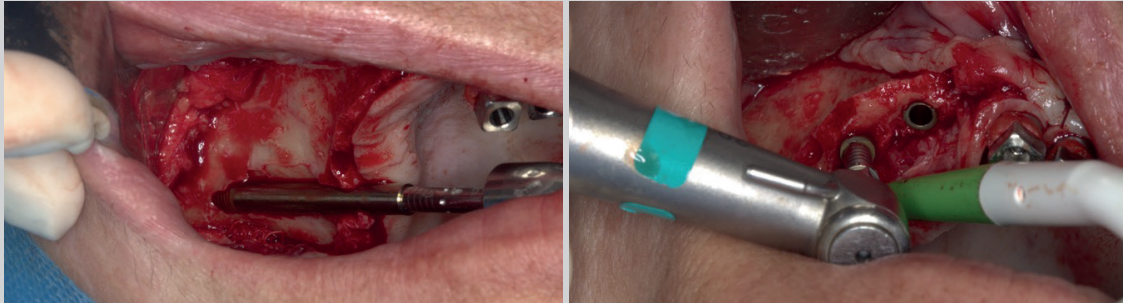
A mucosal incision was made with full-thickness flap reflection of the left hemimaxilla, adequately exposing the bone structures for implant placement. The installation sequence followed a strategic order: first the Zygomatic Plus implant, followed by the conventional implants in the anterior region, and finally the posterior Epikut S PTG Plus implant. After implant placement, mini abutments and transfer components were positioned, and suturing of the operated side was completed.



## INTRAOPERATIVE

Next, the same approach was carried out on the right hemimaxilla, strictly following the same sequence of incision, flap reflection, drilling, and installation of the implants and their respective prosthetic components.

This hemimaxilla-by-hemimaxilla approach allowed for more precise surgical control, favoring tissue management, primary implant stability, and procedural predictability for subsequent immediate loading.




## IMPLANTS USED

**Epikut Implants:** Used in the anterior region of the maxilla, these are conical implants with aggressive macrogeometry and trapezoidal threads that promote high primary stability, even in low bone density situations. Their design optimizes anchorage in type III and IV bone, making them ideal for immediate loading protocols.

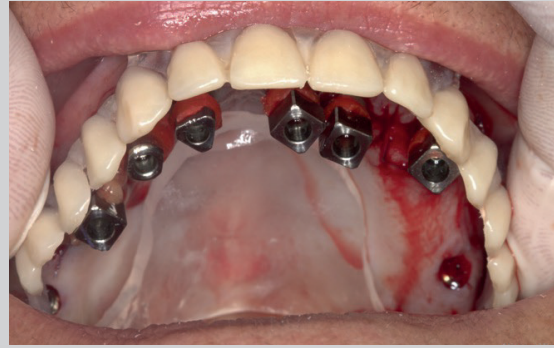
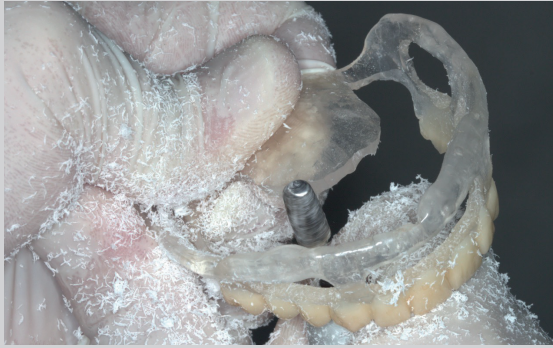
**Zygomatic Plus Implants:** Indicated for severely atrophic maxillae, they allow anchorage in the zygomatic bone without the need for bone grafting. Their extended length and specific design promote stability and load distribution in the premolar region, making them an effective solution for full arch rehabilitations.

**Epikut S PTG Plus Implants:** Placed in the posterior region, they anchor in the pterygoid plate of the sphenoid bone, providing efficient distal support without grafting. Their placement requires advanced anatomical knowledge and refined surgical technique but offers excellent biomechanical results, especially when not directly included in the prosthesis, serving as structural reinforcement.



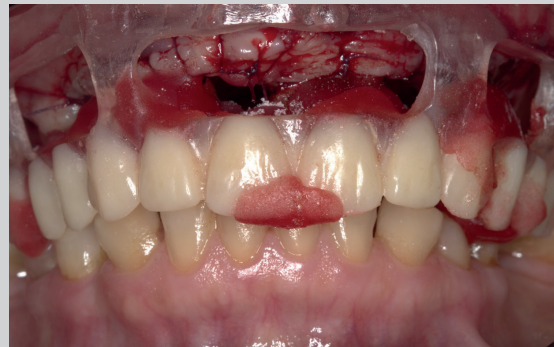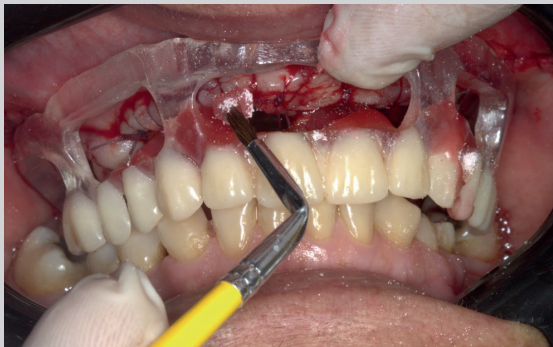## PROSTHETIC PHASE

After suturing, we proceeded with the adjustment of the multifunctional guide, performing selective grinding to ensure its perfect fit over the mini abutments. Then, the transfer copings were rigidly connected to each other with Pattern GC acrylic resin and subsequently attached to the guide itself, providing maximum stability to the assembly during the registrations.



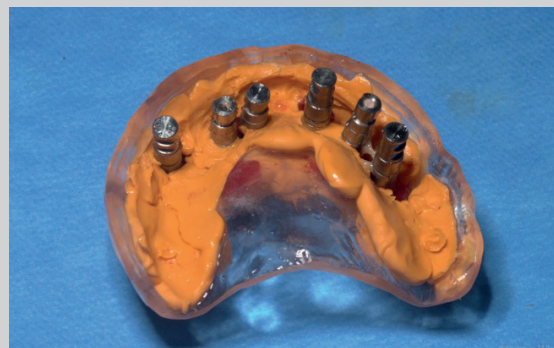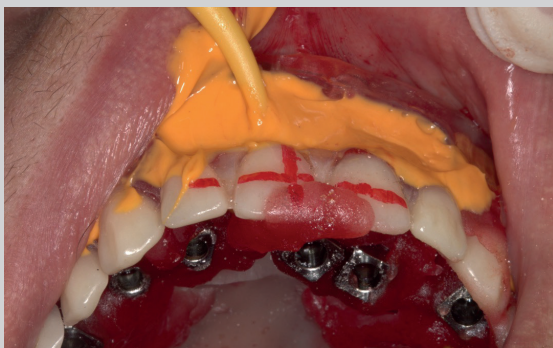
## PROSTHETIC PHASE

The occlusal registration was performed with the same resin, ensuring the reproducibility of the previously established intermaxillary relationship. For the impression, we used addition silicone, carefully applied around the transfer copings, with special attention to avoid infiltration in the operated area.



## PROSTHETIC PHASE

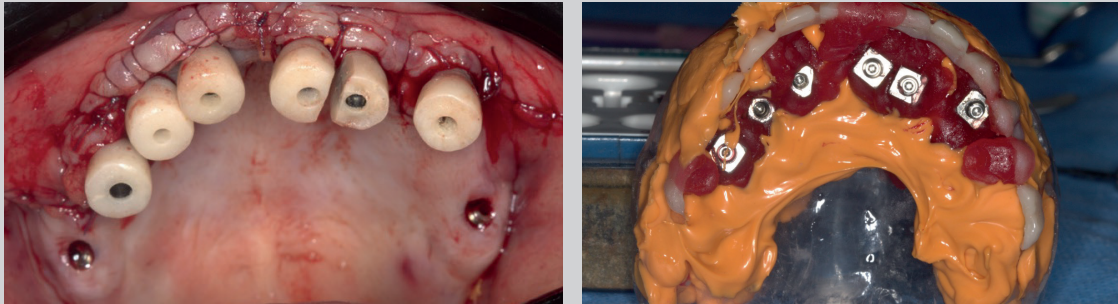
After the final setting of the material, the assembly (multifunctional guide, transfer copings, and impression) was removed as a single unit, and the implant analogs were installed for sending to the laboratory, accompanied by all necessary prosthetic and aesthetic information for the fabrication of the protocol.



## PROSTHETIC PHASE

In the mouth, customized healing abutments were placed to help shape the tissues and facilitate the installation of the definitive protocol after 48 hours.

It is important to note that, although initially planned, the use of Epikut S PTG Plus implants was not necessary, thanks to the excellent stability achieved with the already installed Epikut and Zygomatic Plus implants.

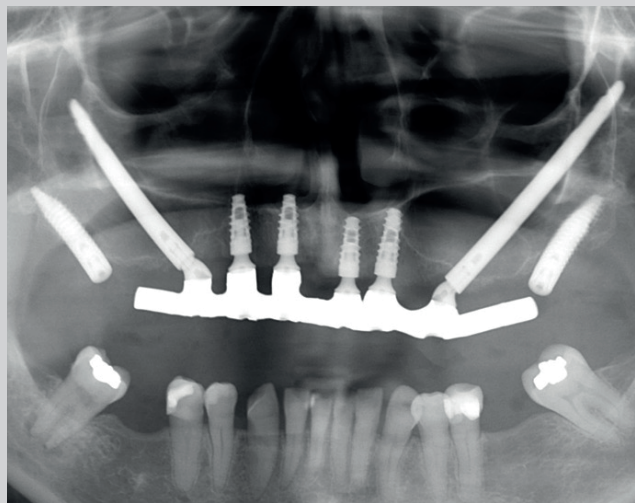


## FINAL RADIOGRAPH

The final panoramic radiograph highlights the strategic distribution of the implants, with proper positioning and satisfactory parallelism. The definitive prosthesis is well adapted to the prosthetic components, which in turn show excellent seating on the implants.

The presence of the Epikut S PTG Plus implants is also noted. These were placed preventively but not used at this stage due to the excellent stability achieved. These implants remain available to receive functional load if future conversion or prosthetic reinforcement becomes necessary.

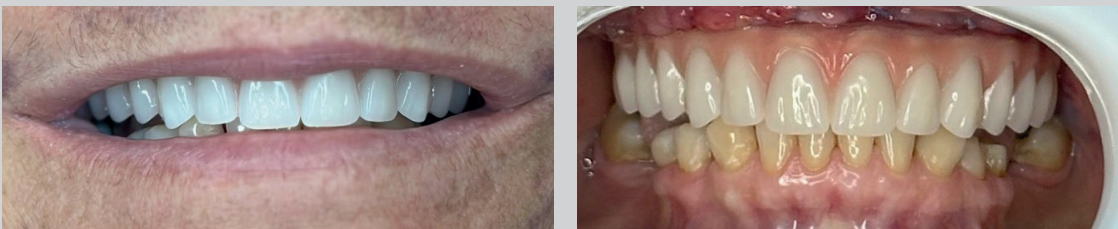
This configuration reinforces the predictability of the planning and the clinical reliability of the Beyond Full Arch approach with immediate loading.



## FINAL RESULT

With the protocol-type prosthesis already installed, the patient resumed her masticatory functions comfortably and efficiently, thanks to the excellent stability of the implants, the strategic distribution of occlusal loads, and the predictability achieved through integrated surgical and prosthetic planning.

In addition to functional recovery, the treatment provided a significant aesthetic transformation, directly impacting the patient's self-esteem, allowing her to smile with greater confidence and assurance. This stage symbolizes the successful completion of a full oral rehabilitation, restoring health, function, and quality of life.



# ATROPHIC MAXILLA REHABILITATIONS: EPIKUT PLUS, EPIKUT LONG PLUS, AND EPIKUT S PTG PLUS IMPLANTS



BY DR. MATHEUS TEIXEIRA

Ambassador's at S.I.N., Specialist in Implant Dentistry – ABCD-PI, Specialist in Prosthodontics – ABCD-PI, Specialist in Periodontics – ABCD-PI

## CASE INTRODUCTION

The use of tilted implants in a graftless approach for immediate loading has been well documented in the literature. This treatment for fully edentulous and often severely resorbed maxillae enables rehabilitation with a fixed prosthesis.

## TREATMENT EXPLANATION

The All On Four technique can avoid bone augmentation procedures in patients with reduced bone volume.

The All On Four concept involves the placement of four implants strategically positioned: two implants placed axially along the alveolar ridge and two implants tilted distally (30-45°). However, in some cases, when planning full-arch rehabilitation for patients with poor bone quality (type IV), it may be advisable to move from the All On Four protocol to the All On Six or Hybrid All On Four protocol.

In this new protocol, implants can also be placed in the most posterior part of the maxilla near the tuberosity and behind the maxillary sinus. This area is called the pterygoid or pterygomaxillary region. The placement of implants through the maxillary tuberosity and into the pterygoid plate is called a pterygoid or pterygomaxillary implant.

The surgical procedure included proper mucoperiosteal flap elevation, broad visualization of the maxilla, and instrumentation with long drills in the distal regions, tangential to the maxillary sinus, aiming to anchor two long implants measuring 3.8 x 18 mm in the canine pillar. In the anterior region, instrumentation was performed for the placement of Epikut implants sized 3.8 x 11.5 mm. In the pterygomaxillary region, two implants sized 4.2 x 18 mm were placed. Immediately after implant placement, the definitive protocol-type prosthesis was fabricated.

## PATIENT RECORD

**Patient:** 62 years old, male

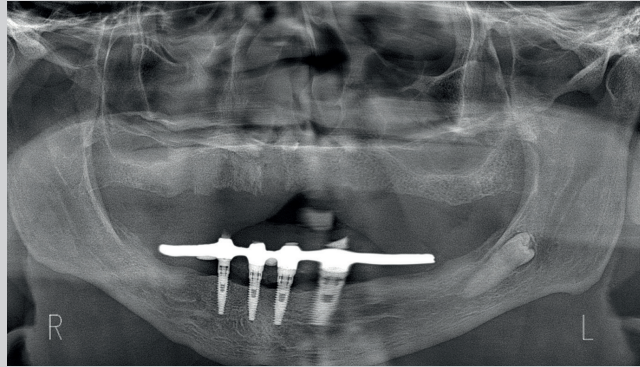
**Chief complaint:** "My denture keeps falling out in front of others."

**Medical history:** ASA II patient with cardiovascular alterations, under medical supervision and compensated with antihypertensive medication.

**Treatment plan:** The plan included treatment of the atrophic maxilla using Epikut Long Plus implants measuring 4.0 x 18 mm in the distal regions of the maxilla and Epikut Plus implants measuring 3.8 x 11.5 mm in the anterior region, along with 4.0 x 18 mm pterygomaxillary implants, distributed using the All On Six technique.

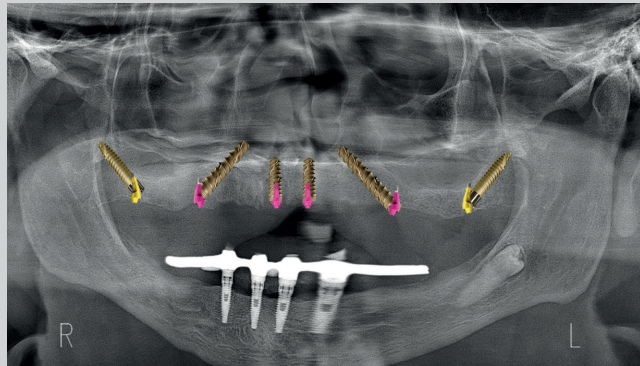
## X-RAY/CT SCAN

Radiographic imaging evaluation revealed bilateral pneumatization of the maxillary sinus and insufficient bone height for conventional implant placement in the posterior maxilla. The treatment plan was made opting not to perform sinus lift or grafting. Thus, two conventional implants were chosen for the premaxilla and two long, angled implants in the distal region, bypassing the maxillary sinus, along with two implants in the pterygoid region to reduce the cantilever.



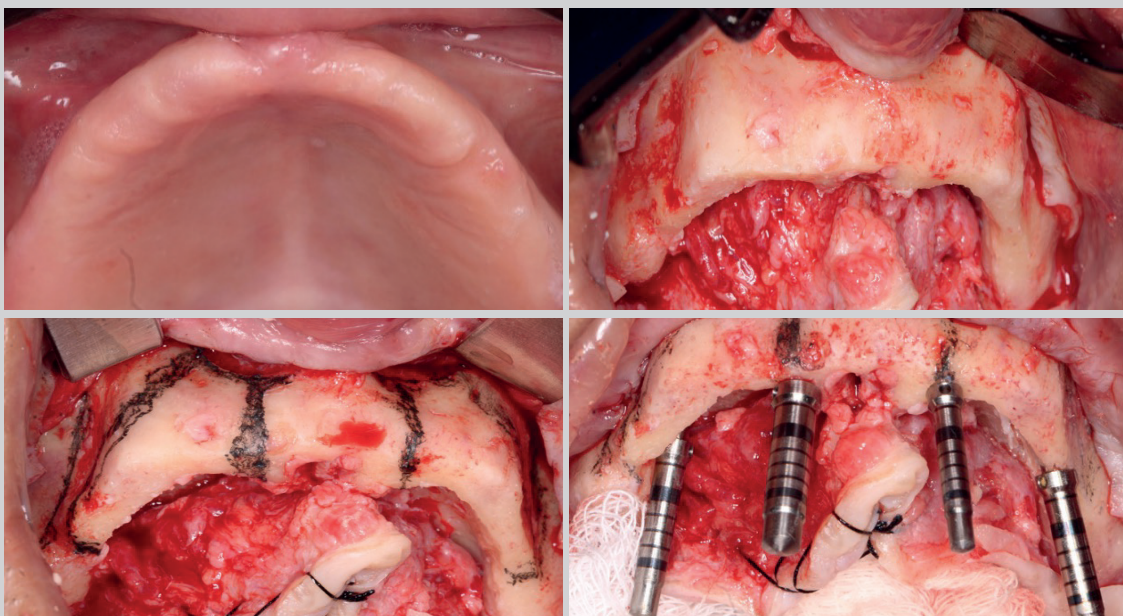
## X-RAY/CT SCAN

Treatment planning using the Epikut Plus, Epikut Long Plus, and Epikut S PTG Plus lines from S.I.N.



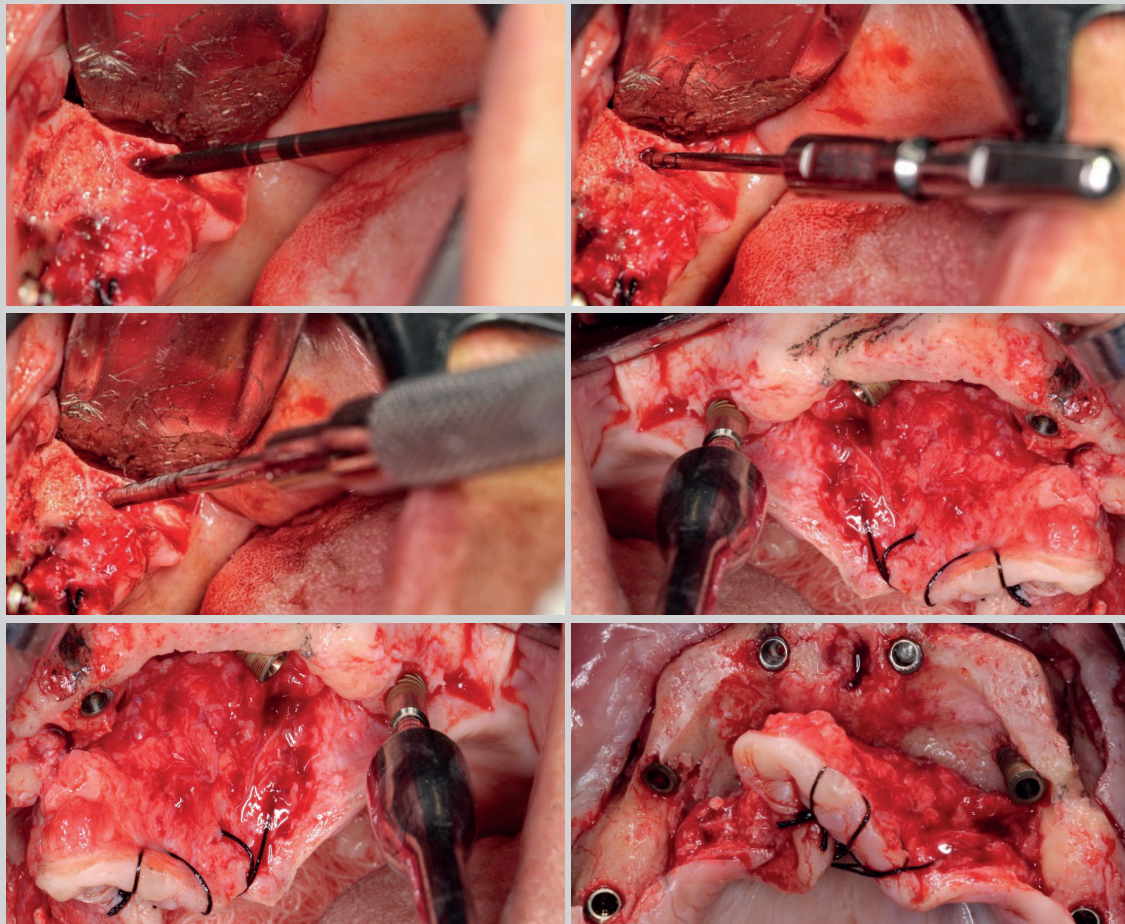
## INTRAOPERATIVE

After full flap elevation to access the maxilla, ridge regularization was performed due to tissue exposure during smiling without the use of prostheses, indicating the need for bone ridge reduction. Next, the implant trajectories were marked, instrumentation was carried out, and the implants were distributed according to the All On Six technique.



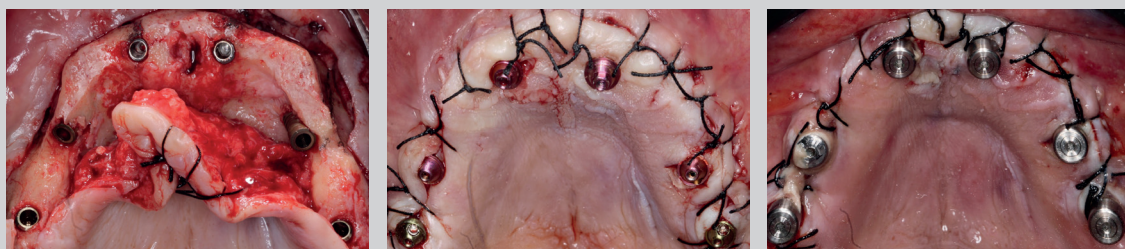
## INTRAOPERATIVE

Immediately after the placement of the anterior and posterior implants, implants were also selected for the tuberosity/pterygoid area—21 implants measuring 4.0 x 18 mm—following the All On Six technique.



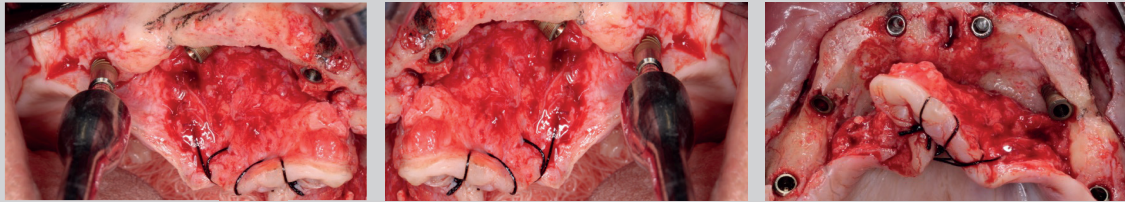
## INTRAOPERATIVE

All implants were placed with insertion torque above 60 N.cm. Immediately afterward, the mini abutments were selected according to the required height and angulation, with the assistance of the S.I.N. direction/angulation indicators.



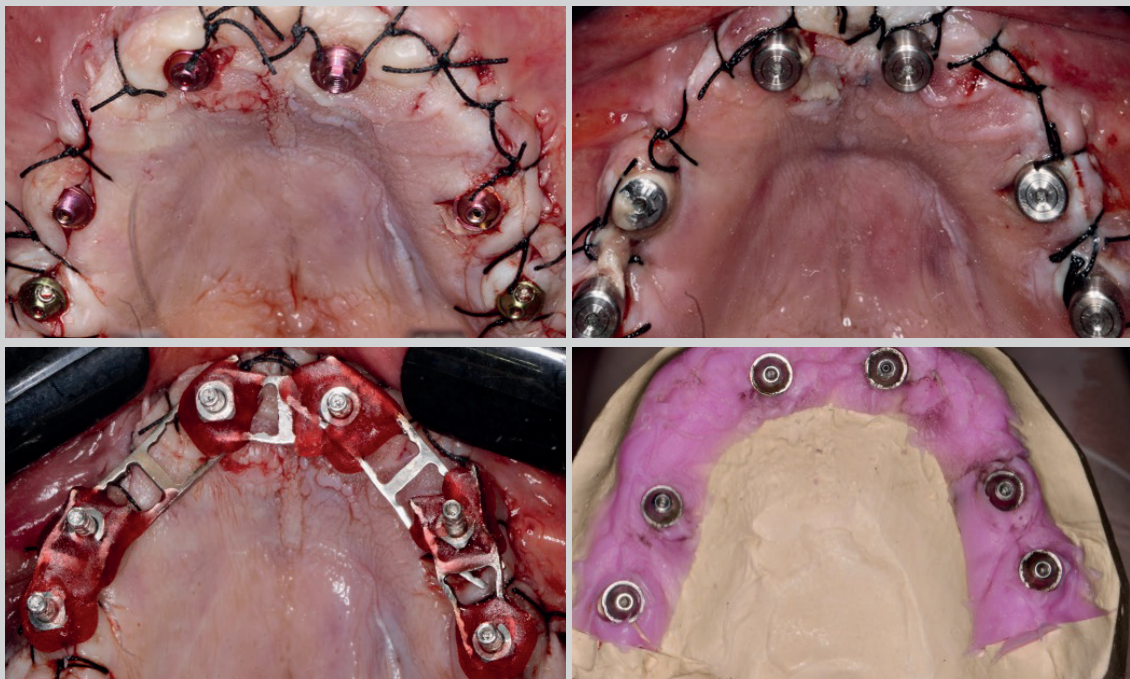
## IMPLANT USED

The implants placed were: Region 12 and 22 (3.8 x 11.5 mm Epikut Plus) / Region 15 and 25 (4.0 x 18 mm Epikut Long Plus) / Region: Pterygoid (4.0 x 18 mm Epikut S PTG Plus).



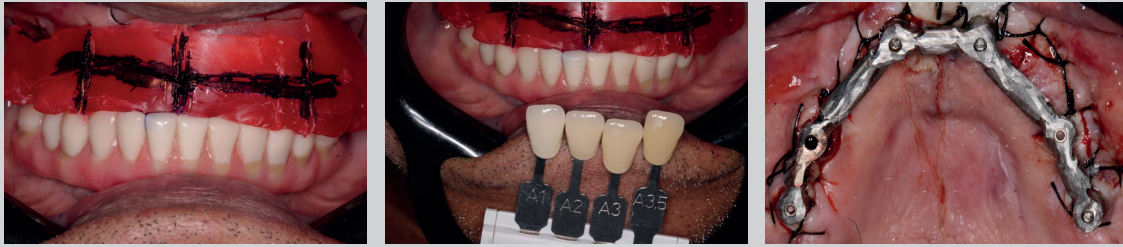## PROSTHETIC PHASE

Next, the steps for installing the angled and straight S.I.N. mini abutments were performed. Immediately afterward, an open-tray impression was taken using transfer copings for provisional rehabilitation with immediate loading, as planned.



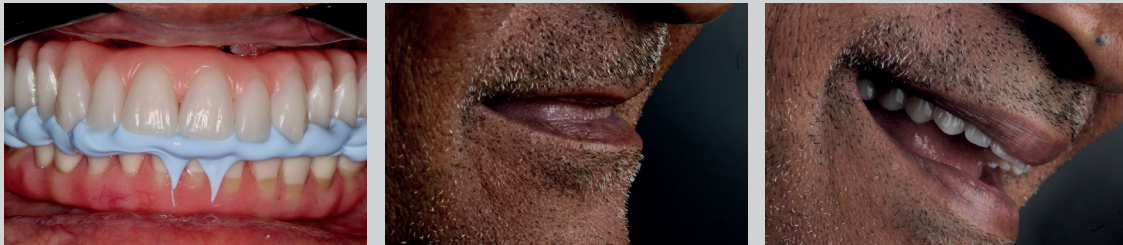## PROSTHETIC PHASE

Next, the laboratory steps for the fabrication of the definitive protocol-type prostheses were carried out.



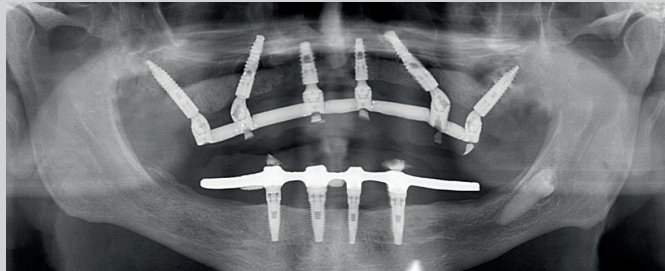
## PROSTHETIC PHASE

Following the measurements obtained from the wax-up plan and the comparison with "Before and After" photos for smile harmonization.

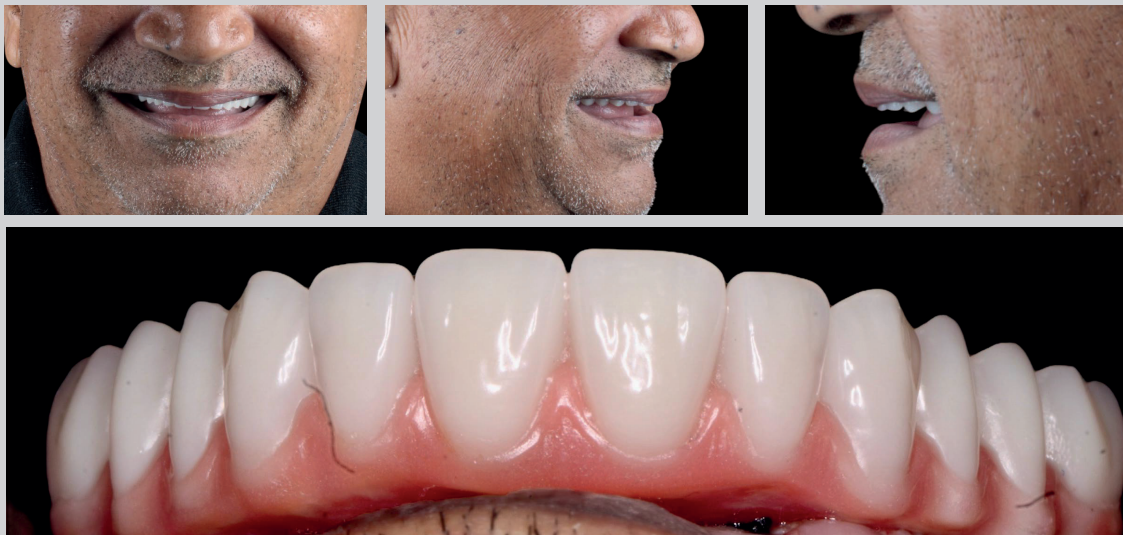

## FINAL RADIOGRAPH

Radiographic aspect showing the conventional Epikut Plus, Epikut Long Plus, and Epikut S PTG Plus implants in the maxillary rehabilitation, as well as the lower implants.



## FINAL RESULT



# EPIKUT LONG IN THE TREATMENT OF SEVERELY ATROPHIC MAXILLA



BY DR. MAIOLINO THOMAZ FONSECA OLIVEIRA

Doctor in CTBMF and Implant Dentistry from the Federal University of Uberlândia

Oral and Maxillofacial Surgeon at the University Hospital of the Federal University of Uberlândia

## CASE INTRODUCTION

A 63-year-old female patient with severe maxillary atrophy, wearing a complete upper denture, sought treatment for oral rehabilitation using an implant-supported prosthesis.

## TREATMENT EXPLANATION

The therapeutic approach includes the use of Epikut Long implants in the distal regions (implants measuring 3.8 x 22 mm) and implants measuring 3.8 x 11.5 mm in the anterior maxillary region. After flap elevation and maxillary exposure, the implants were distributed following the All On Four technique and installed via palatal access. The distal implants were placed tilted, tangential to the anterior wall of the maxillary sinus, aiming for anchorage in the canine pillar.

## PATIENT RECORD

**Patient:** 63 years old, female.

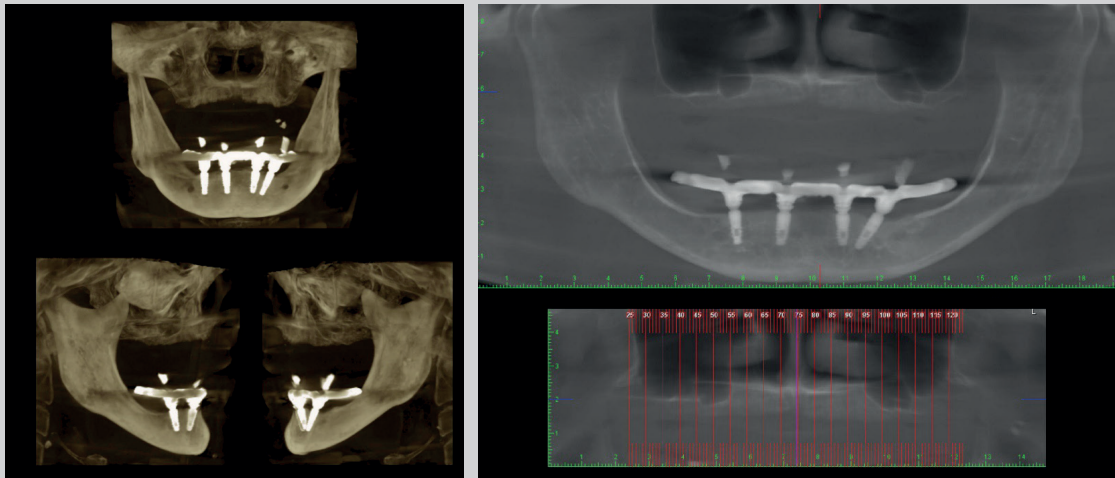
**Chief complaint:** The patient reported instability of the complete denture, requiring implant rehabilitation for improved masticatory performance.

**Medical history:** Hypertensive patient using antihypertensive medication.

**Treatment plan:** The treatment plan includes implant distribution following the All On Four technique, using Epikut Long implants in the distal regions and conventional-sized implants in the anterior maxillary region.

## X-RAY/CT SCAN


Tomographic reconstruction and coronal section showing significant pneumatization of the maxillary sinus.



24

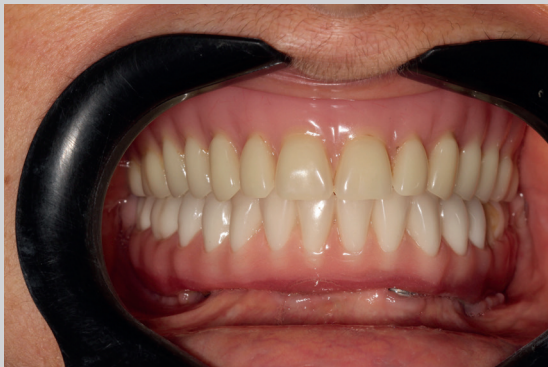## X-RAY/CT SCAN

Sagittal sections revealing severe maxillary atresia.



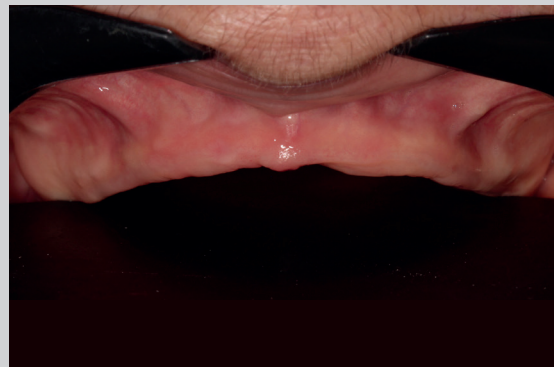
**BEFORE**

*Intraoral view showing a protocol-type lower prosthesis and a removable upper prosthesis.*



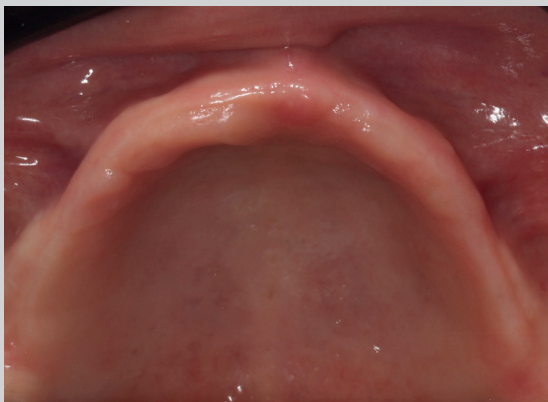
**BEFORE**

*Intraoral view of the maxilla without the removable prosthesis.*



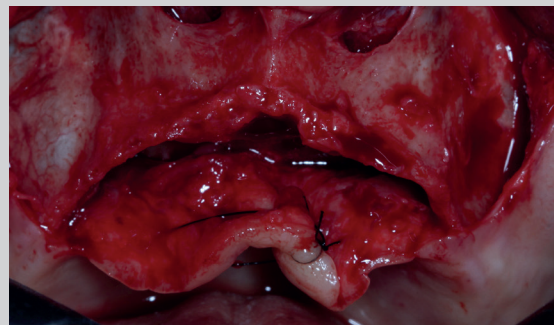
**BEFORE**

*Occlusal view.*



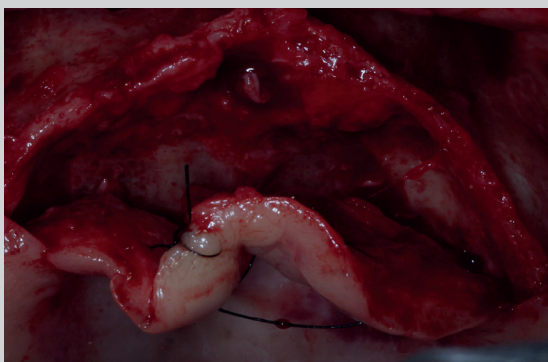
**STEP-BY-STEP OF THE PROCEDURE**

*Wide access to the maxilla, exposing the palatal plate, maxillary sinus, and piriform aperture. Mucosal detachment of the nasal mucosa was performed to achieve bicortical anchorage of the Epikut Long implants.*



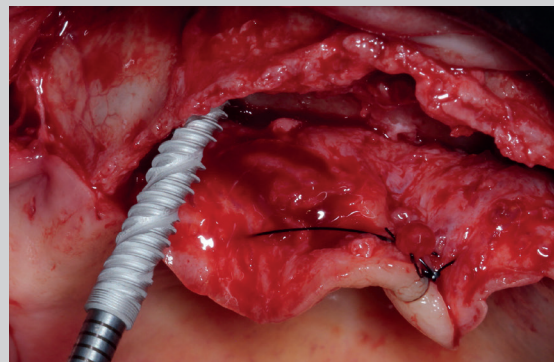
**STEP-BY-STEP OF THE PROCEDURE**

*Palatal flap elevation aimed at facilitating the palatal approach.*



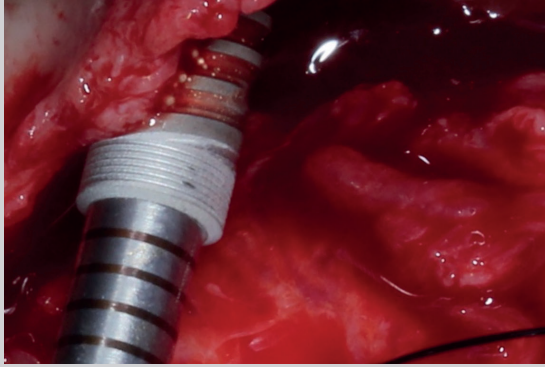
**INTRAOPERATIVE**

*Placement of the distal Epikut Long implants measuring 3.8 x 22 mm.*

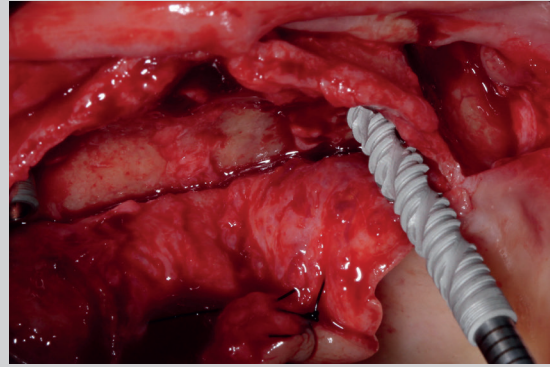


**INTRAOPERATIVE**

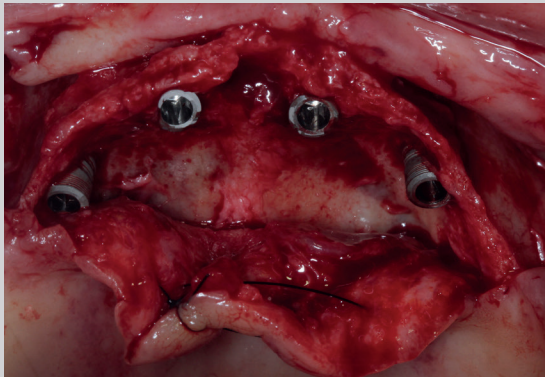
*Relation of the implant cervical region with the residual alveolar process plate.*

**INTRAOPERATIVE**

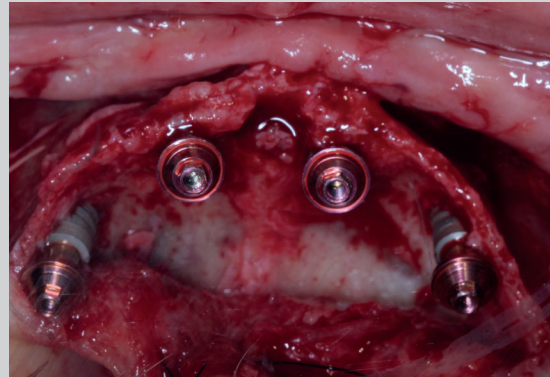
*Placement of the distal Epikut Long implants measuring 3.8 x 22 mm.*

**INTRAOPERATIVE**

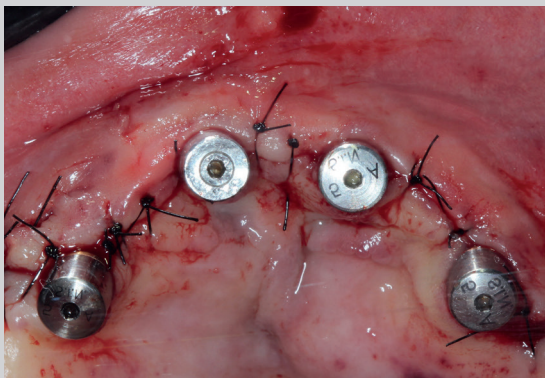
*Distribution of the Epikut Long implants following the All On Four protocol.*

**INTRAOPERATIVE**

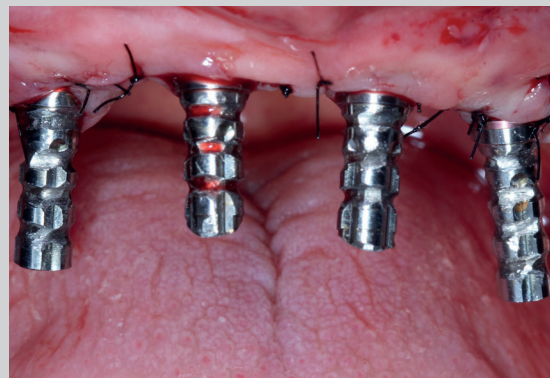
*Placement of mini abutments with 3.5 mm transmucosal height.*

**STEP-BY-STEP OF THE PROCEDURE**

*Suturing of the surgical wound with placement of mini abutment protectors.*

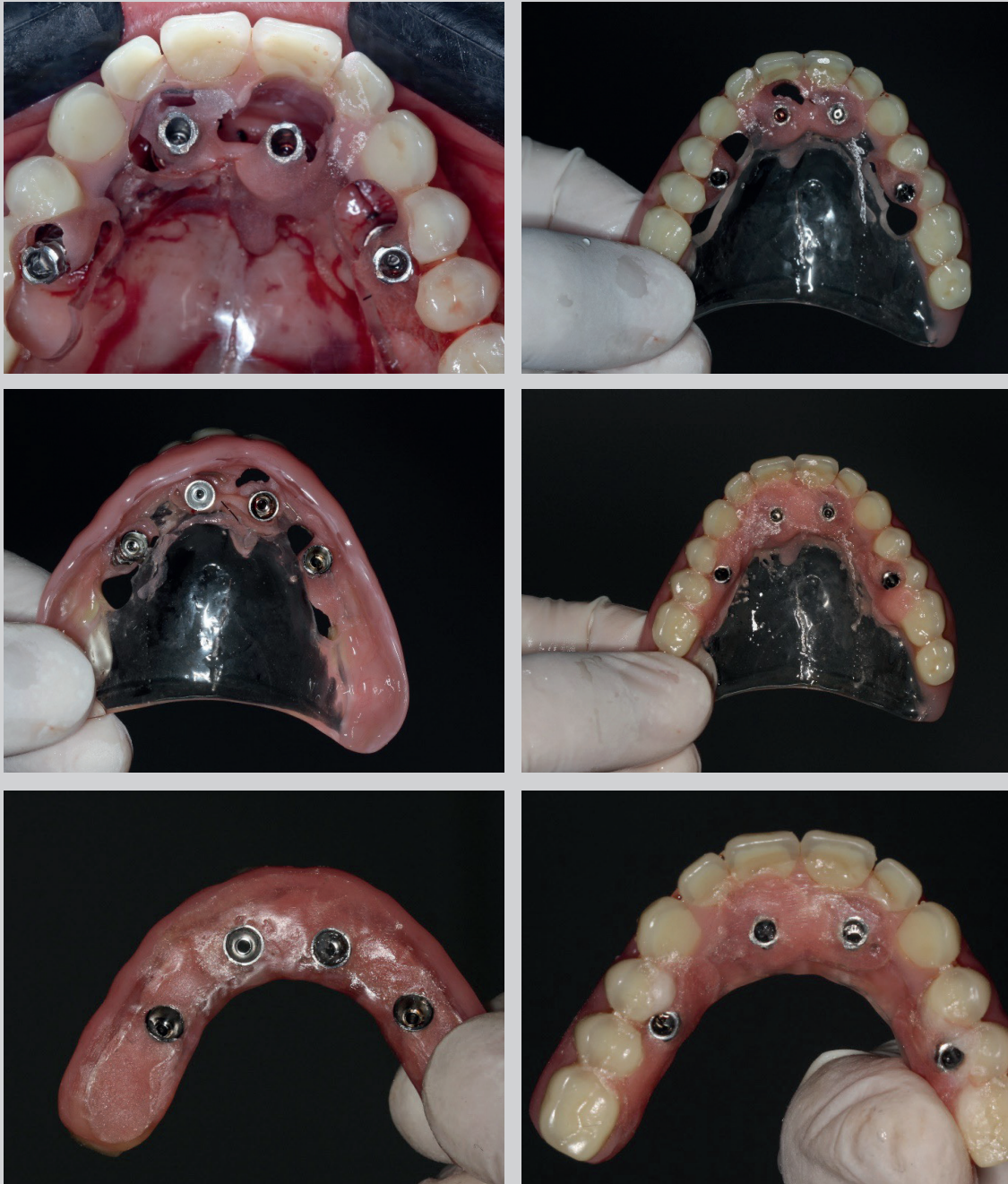
**STEP-BY-STEP OF THE PROCEDURE**

*Placement of the provisional titanium cylinders.*



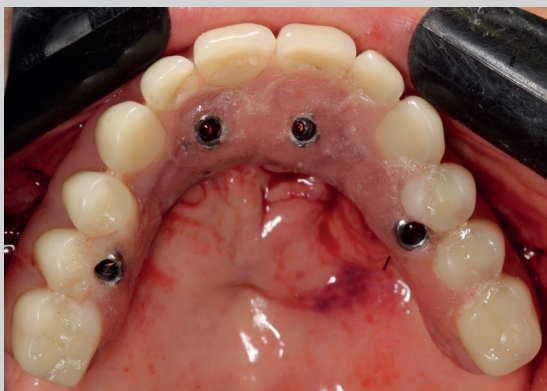## PROVISIONALIZATION

*Impression of the removable prosthesis and fabrication of the provisional protocol prosthesis.*

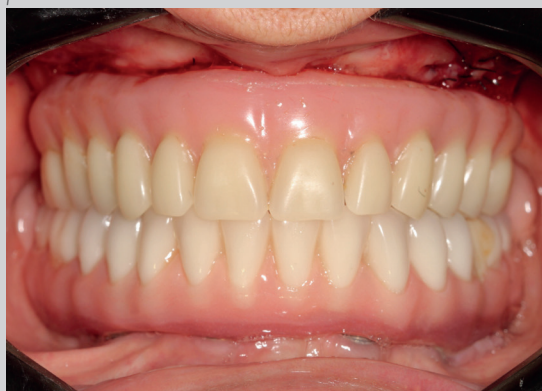

**PROVISIONALIZATION**

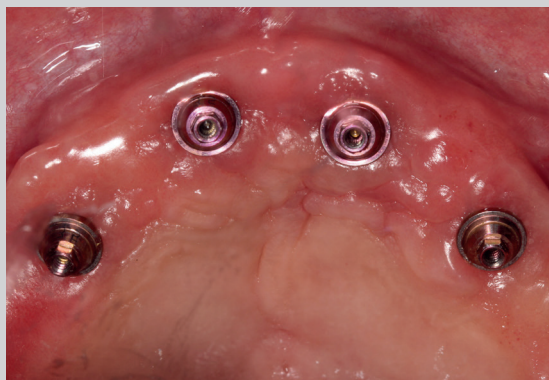Occlusal view of the implant emergence.

**PROVISIONALIZATION**

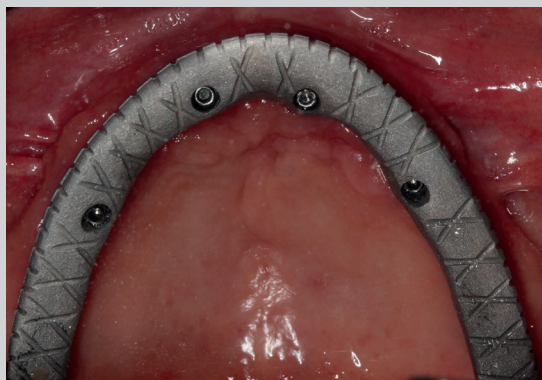Intraoral appearance after impression of the removable prosthesis.

**PROSTHETIC PHASE****PROSTHETIC PHASE**

Após período de osseointegração foi realizada a moldagem e sequência para construção da prótese definitiva.

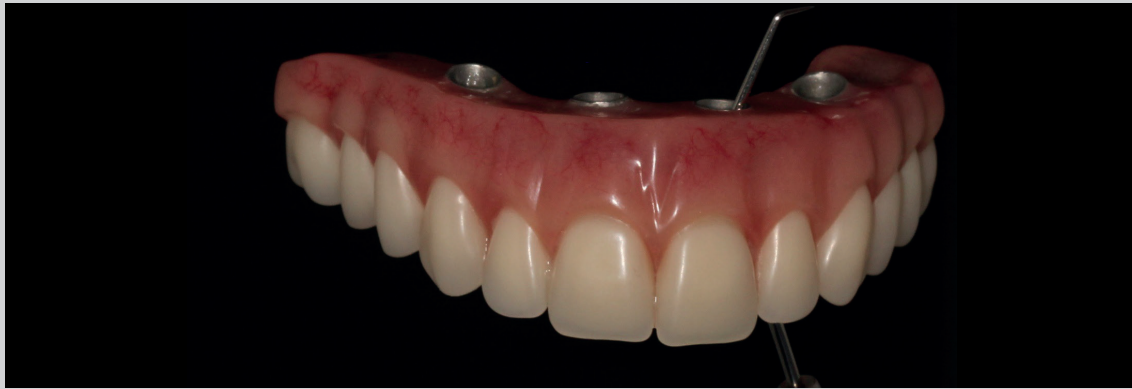**PROSTHETIC PHASE**

Checagem da infraestrutura metálica.



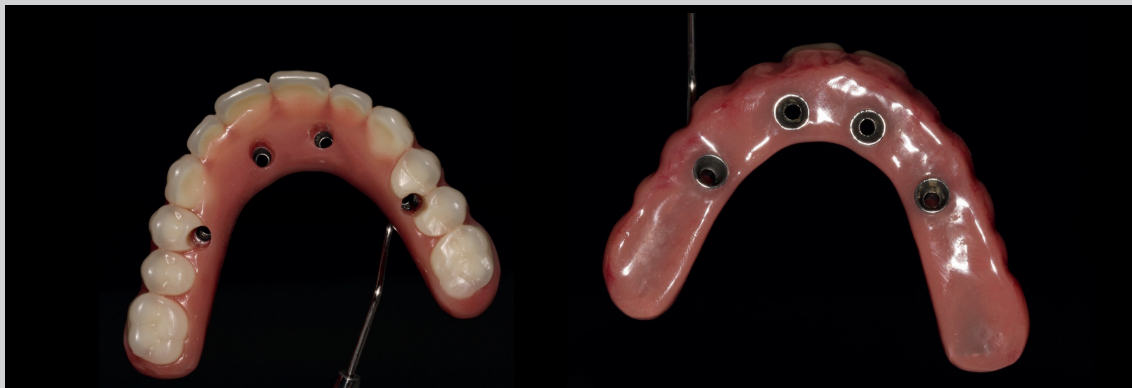## PROSTHETIC PHASE

*Aspects of the definitive prosthesis.*



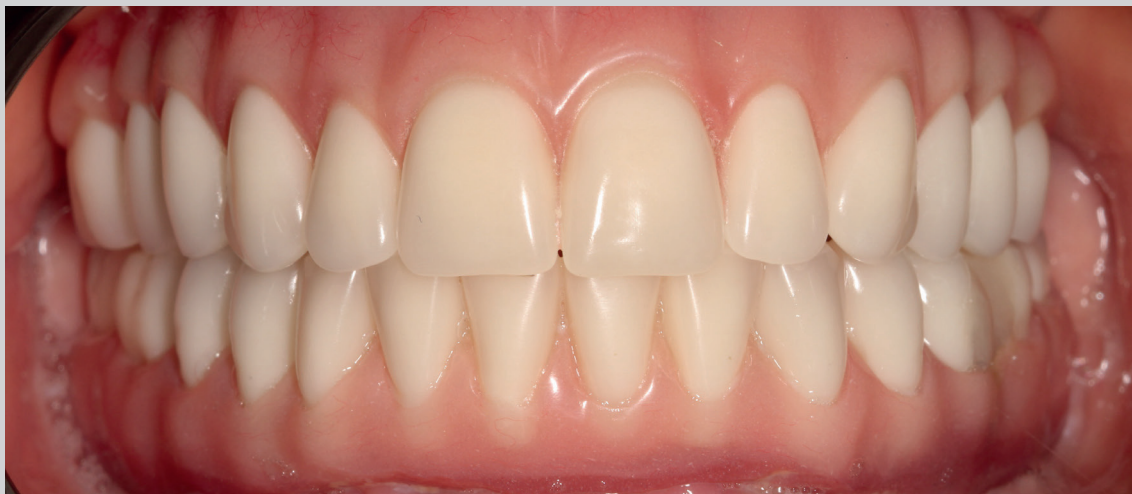## PROSTHETIC PHASE

*Implant emergence in relation to the prosthesis.*



## FINAL RESULT

*Final intraoral appearance.*



# ZYGOMATIC PLUS



TEAM OF THE CENTER FOR TEACHING AND RESEARCH IN  
IMPLANTODONTICS AT UFF/RJ

Prof. Dr. Priscila Casado, Prof. Dr. Aldir Machado, Prof. Dr. Gustavo Oliveira, Prof. Bruno Rangel,  
Prof. Dr. Alexandre Montenegro, Doctoral Candidates: Prof. Thainara Salgueiro, Student: Fernando  
Azevedo, Guest: Prof. Marcus Vinicius Siqueira, and Advisor: Prof. Fernando Giovanela

## CASE INTRODUCTION

Clinical case of zygomatic implants combined with conventional implants in the anterior region, with immediate provisionalization and a resin-printed prosthesis featuring extrinsic staining.

## TREATMENT EXPLANATION

Placement of two Zygomatic Plus implants combined with two conventional implants placed in the region of teeth 11 and 21, preceded by extraction of teeth 21, 22, and 23, and bone smoothing. The procedure included scanning, digital design and 3D printing of the prosthesis, followed by immediate installation.

## PATIENT RECORD

**Patient:** 81 years old, male.

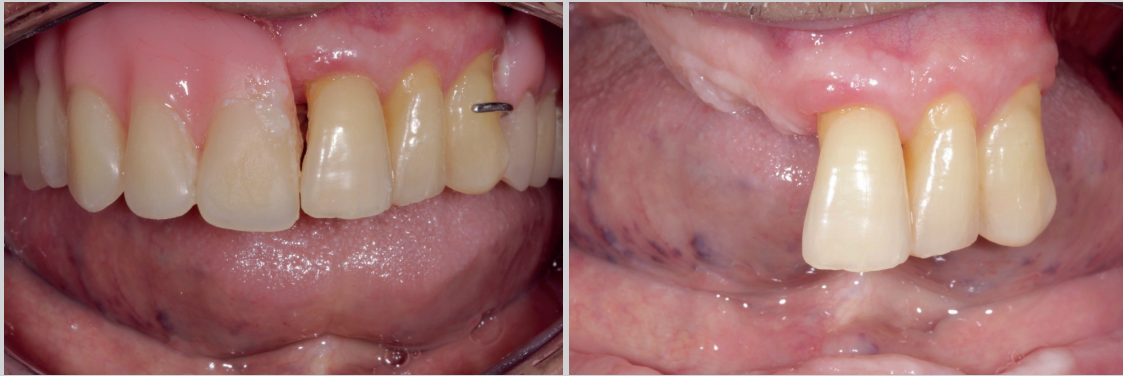
**Chief complaint:** The patient reported difficulty chewing (“SIC”).

**Medical history:** Hypertensive, has gastritis, former smoker, uses simvastatin, losartan, and omeprazole.

**Treatment plan:** Due to insufficient posterior bone remnant for conventional implant placement, a combination of two implants in the anterior region with two Zygomatic Plus implants was chosen.

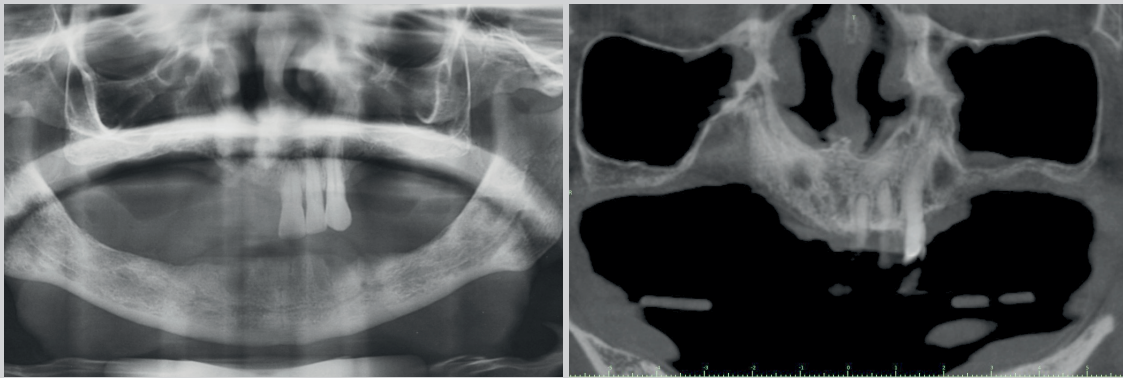
## BEFORE

*Initial clinical appearance.*



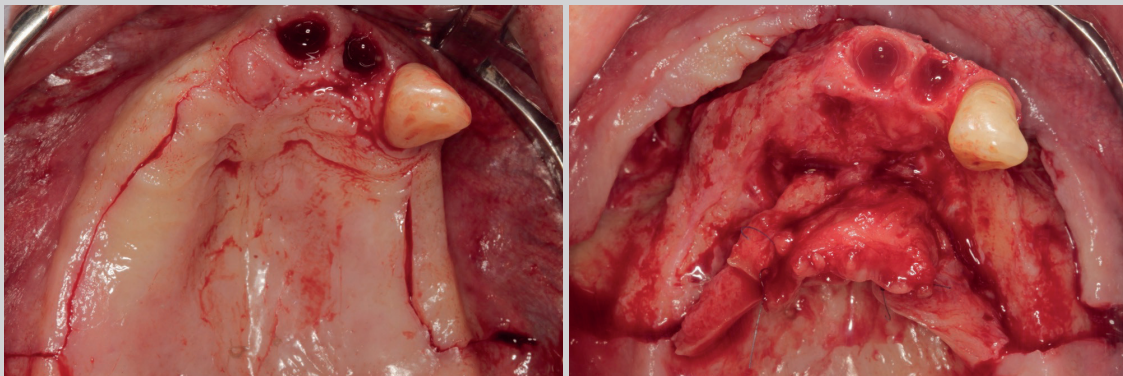
## X-RAY/CT SCAN

*Initial panoramic X-ray and panoramic tomographic slice.*



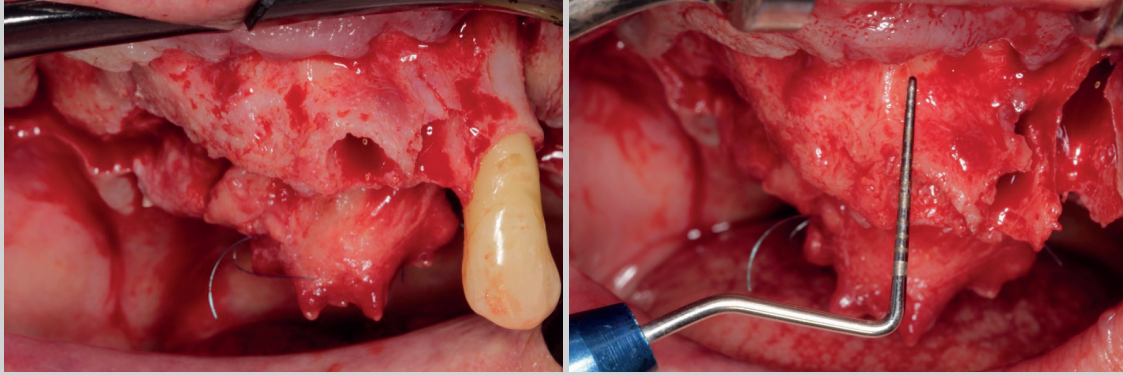
## STEP-BY-STEP OF THE PROCEDURE

*Palatinized incision relative to the alveolar ridge with distal releasing incisions at the level of the zygomatic pillar and full flap elevation.*



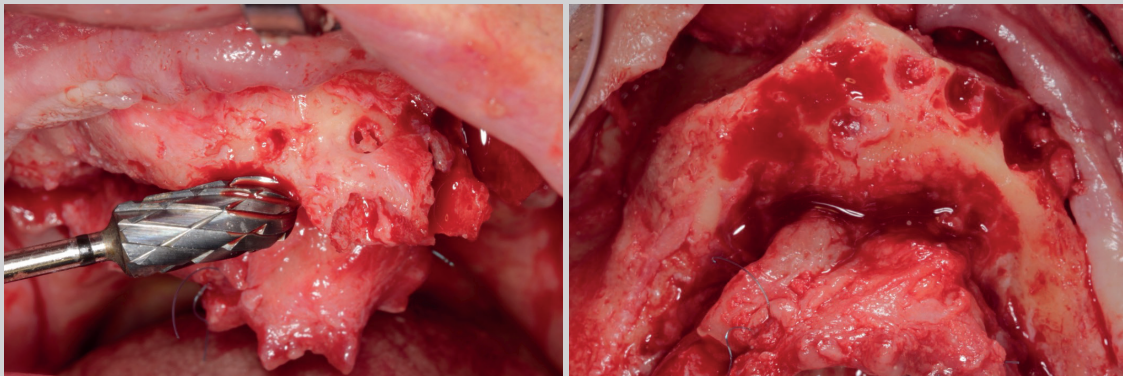
## STEP-BY-STEP OF THE PROCEDURE

Measurement of the required smoothing of the remaining alveolar process, guided by tomography, following extraction of teeth 21, 22, and 23.



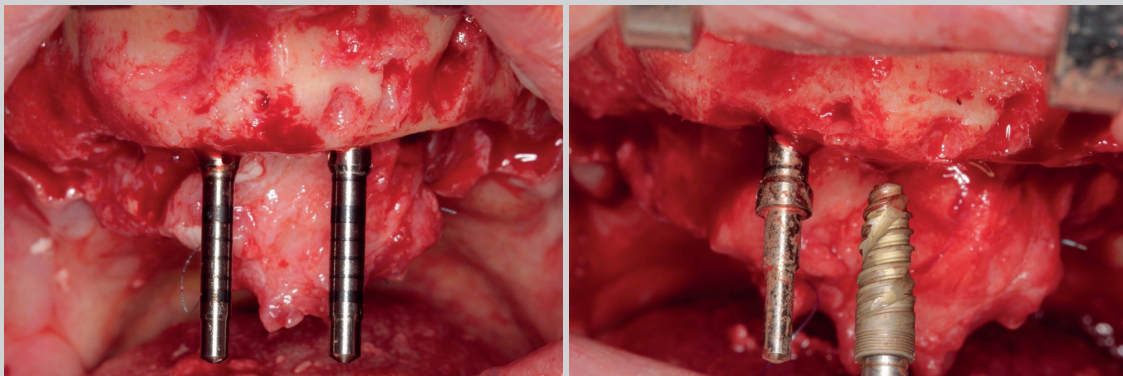
## STEP-BY-STEP OF THE PROCEDURE

Bone smoothing with a tungsten bur and occlusal view of the prepared ridge.



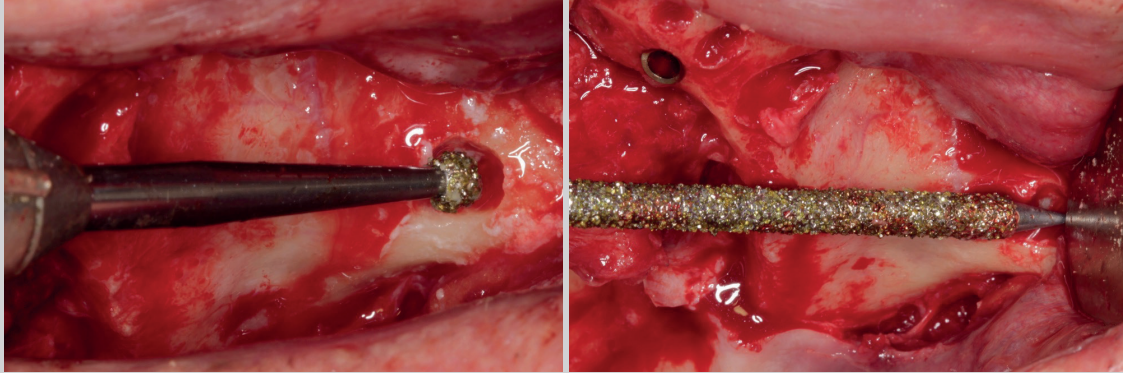
## INTRAOPERATIVE

Parallel pins for implants in regions 11 and 21, and Epikut implants measuring 3.5 x 10 mm.



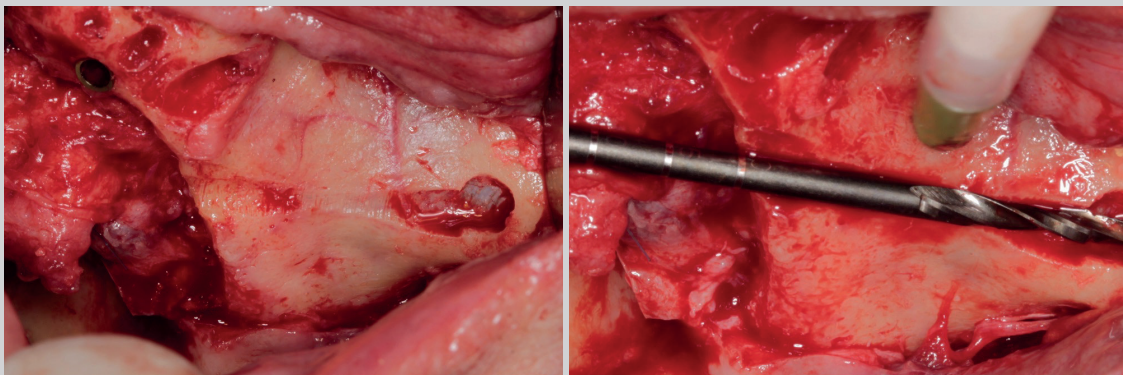
## INTRAOPERATIVE

Initial marking with a diamond round bur on the zygomatic arch and preparation of the osteotomy site with a 4.0 mm diamond bur.



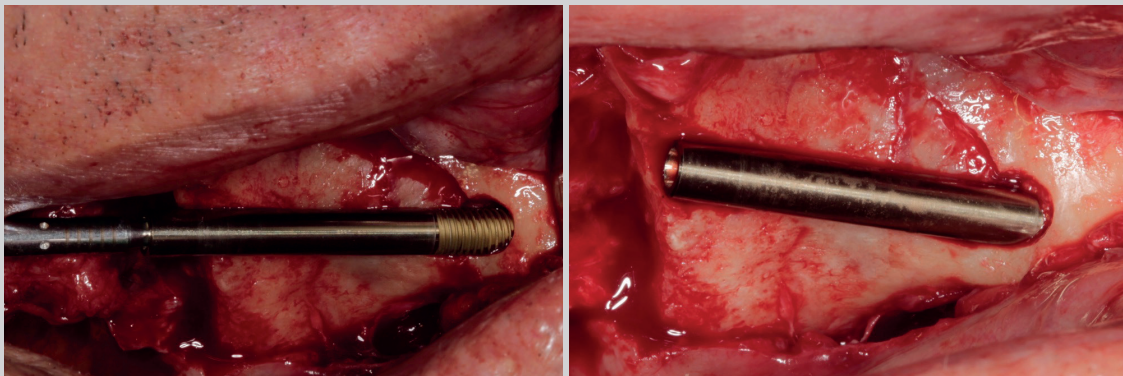
## INTRAOPERATIVE

Surgical site initiated, and drilling performed with lance-shaped burs of 1.8 mm and 2.35 mm.



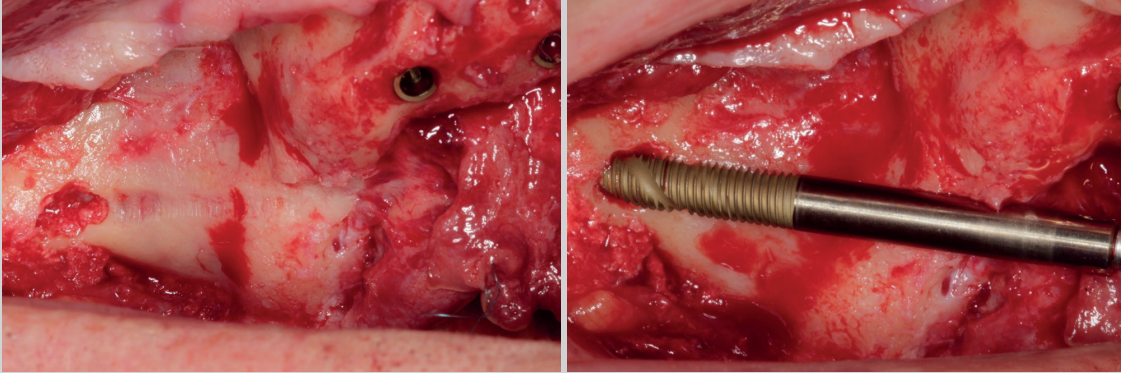
## IMPLANT USED

Left Zygomatic Plus implant placed with 60 N.cm torque.

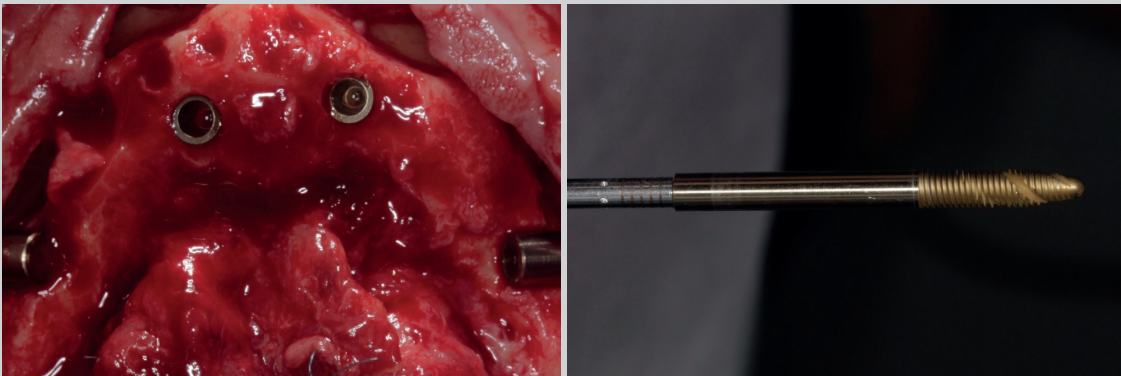


**IMPLANT USED**

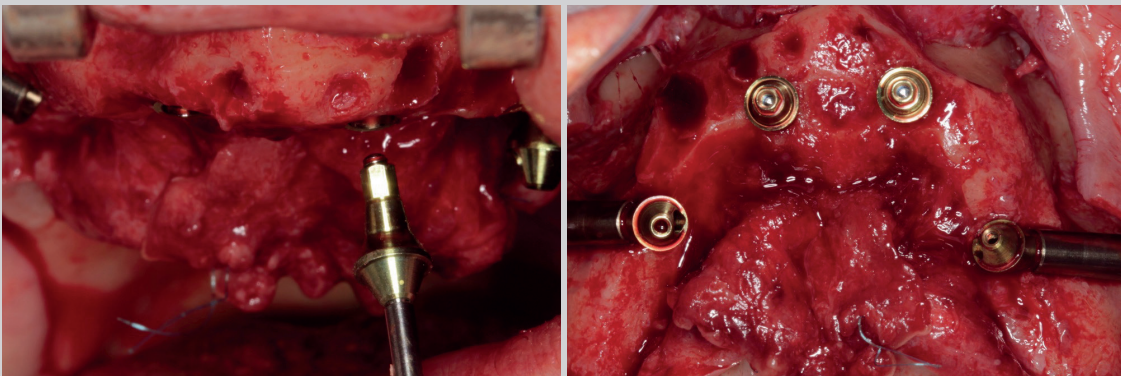
*Surgical site and right-side Zygomatic Plus implant placed with 60 N.cm torque.*

**IMPLANT USED**

*Implants finalized in position.*

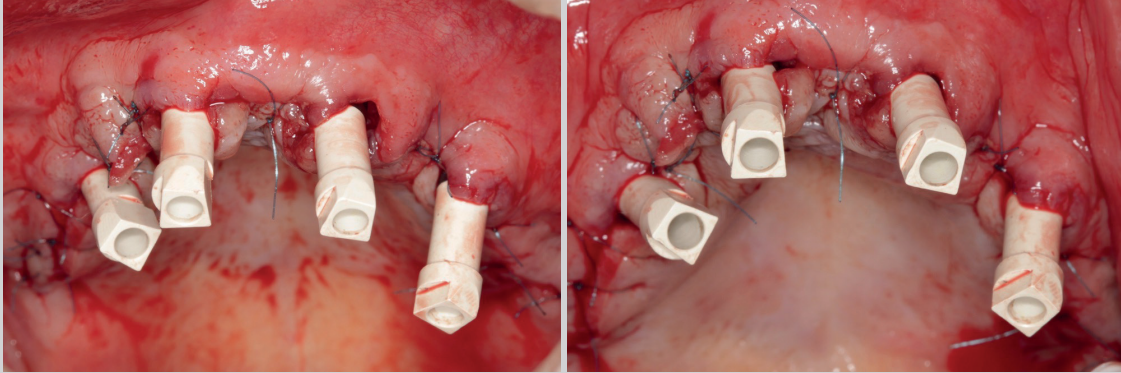
**INTRAOPERATIVE**

*Placement of 45° angled mini abutments, torqued to 20 N.cm.*



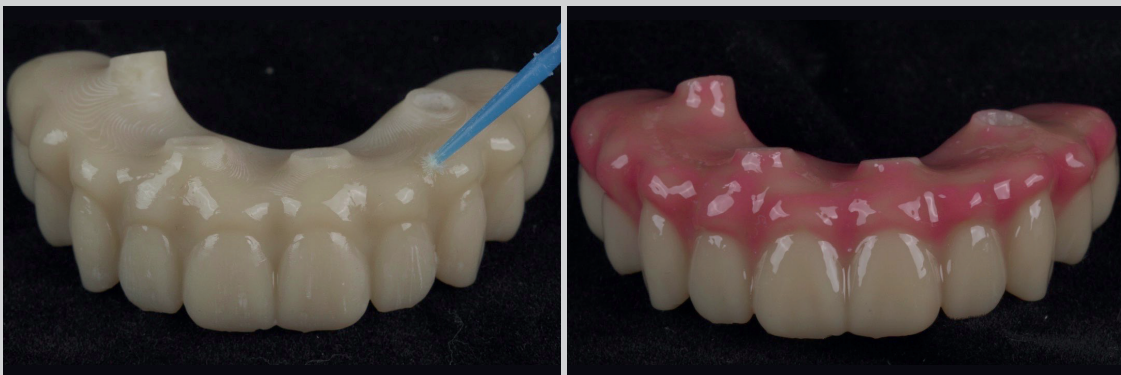## PROSTHETIC PHASE

Scan jigs in position, suturing, and scanning.



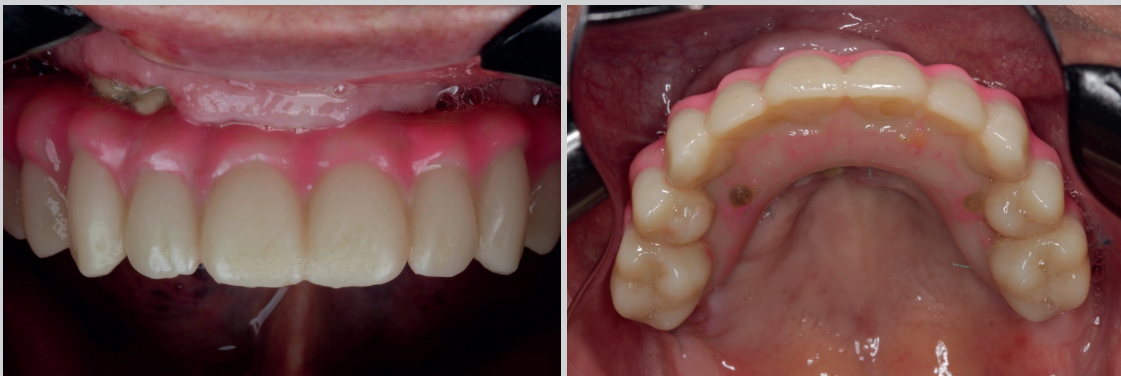## PROSTHETIC PHASE

Prostheses prototyped before and after extrinsic staining.



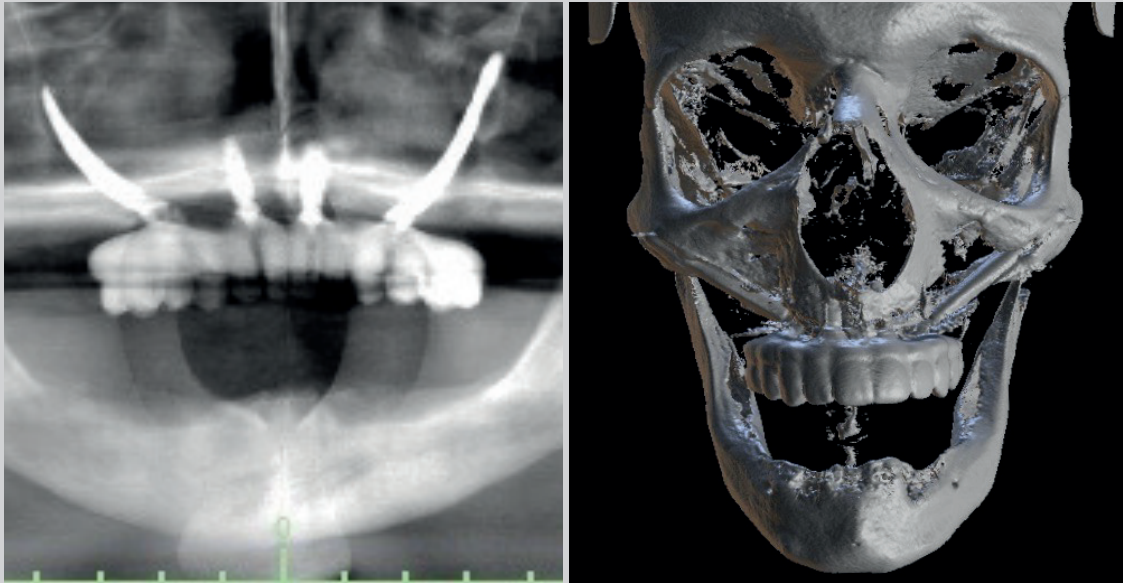
## PROSTHETIC PHASE

Prostheses installed 24 hours after surgery.

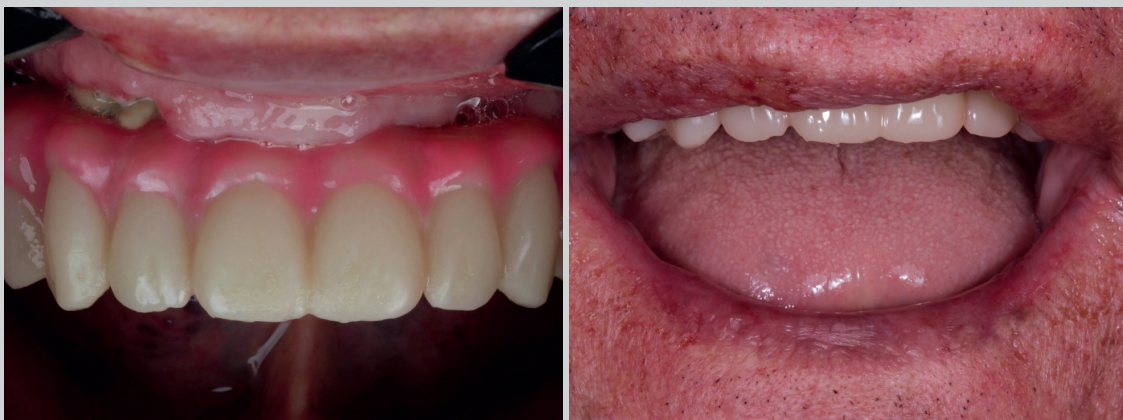

**FINAL CT SCAN**

*Post-surgical CT scan images.*

**FINAL RESULT**

*Prosthesis after 1 week.*



# FULL MAXILLARY REHABILITATION WITH CONVENTIONAL, ZYGOMATIC, AND PTERYGOID IMPLANTS



## BY DR. GUILHERME AMARAL

Specialist in Implant Dentistry from ABO/AL, Specialist and Master in Prosthodontics from São Leopoldo Mandic Campinas, PhD candidate in Implant Dentistry at São Leopoldo Mandic Campinas. President of ABO/AL and S.I.N. Ambassador.

## CASE INTRODUCTION

35-year-old female patient with compromised dental elements due to dental caries and extensive coronal destruction, along with severe bone loss in the anterior maxilla. Based on the critical condition of the jaws, the decision was made to remove the remaining teeth and proceed with full rehabilitation using dental implants.

## TREATMENT EXPLANATION

35-year-old female patient with compromised dental elements due to dental caries and extensive coronal destruction, along with severe bone loss in the anterior maxilla. Given the critical condition of the jaws, the decision was made to remove the remaining teeth and proceed with full rehabilitation using dental implants.

Due to the degree of atrophy in the anterior maxilla, the proposed treatment involved the use of anterior exteriorized Zygomatic Plus implants anchored in zone 1 of the maxilla, followed by conventional implants in the posterior region. Additionally, an Épikut S PTG Plus implant was placed on the right side to improve load distribution and optimize the composite torque for immediate maxillary loading. In the mandibular region, a conventional All-on-Four approach was planned.

## PATIENT RECORD

**Patient:** 35 years old, female.

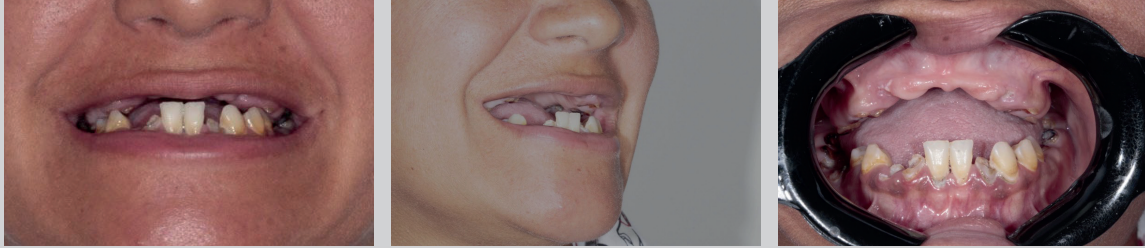**Chief Complaint:** “I can’t eat properly and I’m embarrassed about my smile.”

**Medical History:** No underlying diseases or medications contraindicating the rehabilitation procedure were reported. The patient mentioned experiencing depression and denied any parafunctional habits.

**Treatment Plan:** Total removal of the remaining teeth in the maxilla and mandible was planned, followed by full rehabilitation of both jaws. The procedure was performed in an outpatient setting under sedation with 7.5 mg of midazolam.

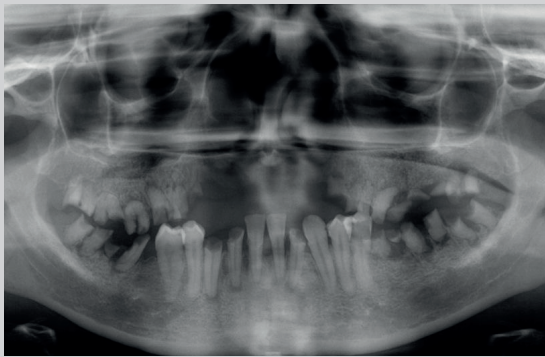
## BEFORE

Preoperative extraoral and intraoral images.



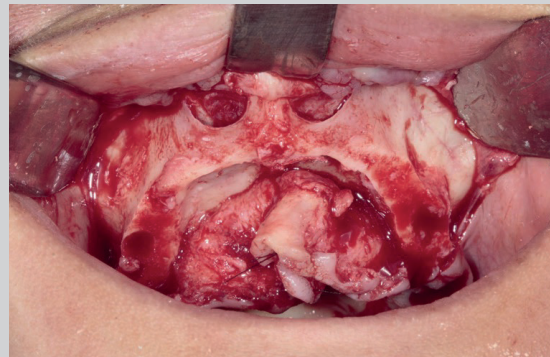
## X-RAY/CT SCAN

Preoperative panoramic radiograph showing remaining teeth with extensive coronal destruction and absence of bone in the anterior maxilla region.



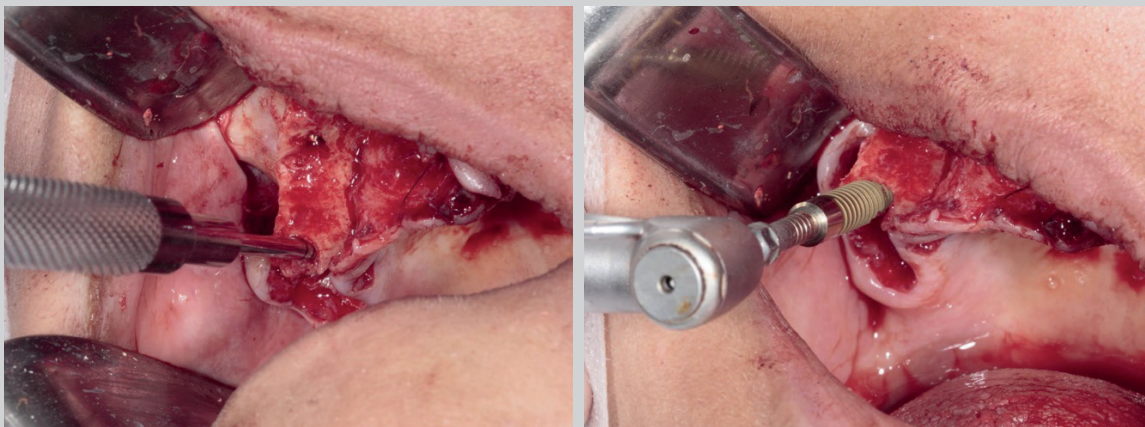
## STEP-BY-STEP OF THE PROCEDURE

Initial image of the maxillary surgical access after removal of the compromised dental elements.



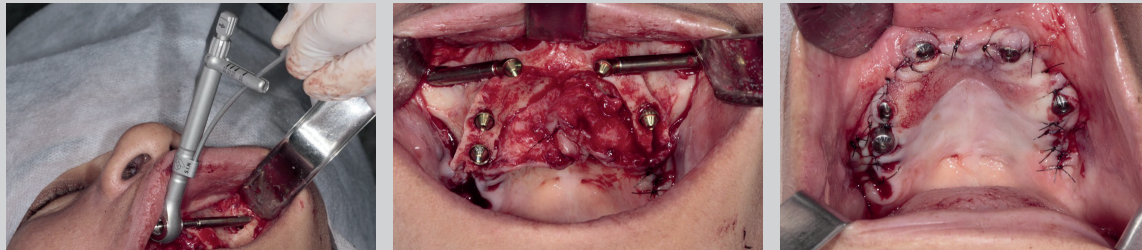
## INTRAOPERATIVE

In the posterior region of the right maxilla, surgical preparation was performed with the aid of expanders, followed by the placement of a 4.5 x 20 mm Epikut S PTG Plus implant with a torque of 45 N.cm to improve masticatory load distribution and achieve composite torque to ensure immediate loading.



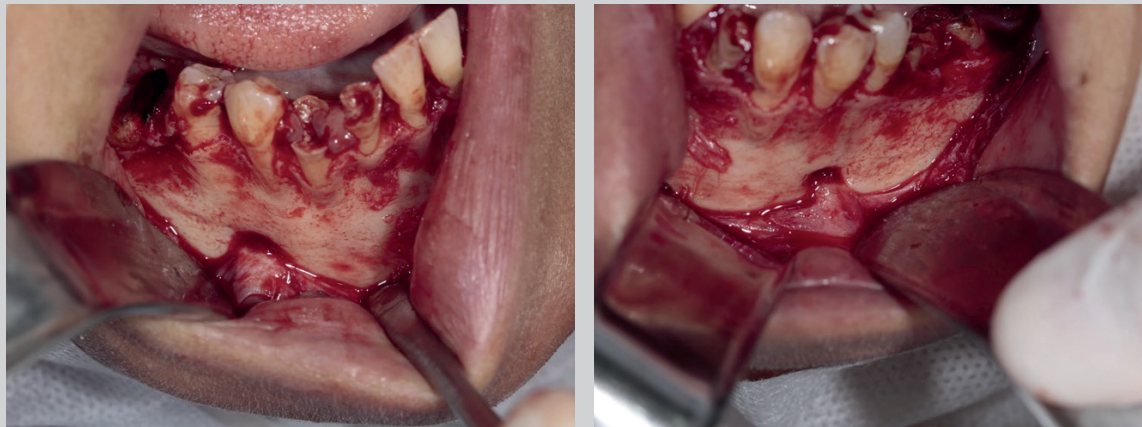
## INTRAOPERATIVE

*In the anterior region, surgical preparation was performed for the placement of anterior Zygomatic Plus implants using a diamond drill to create the exteriorized channel, followed by the placement of 4.0 x 50 mm (right side) and 4.0 x 47.5 mm (left side) implants, as well as conventional 3.8 x 15 mm Strong SW implants, which were then fitted with mini abutments and sutured.*



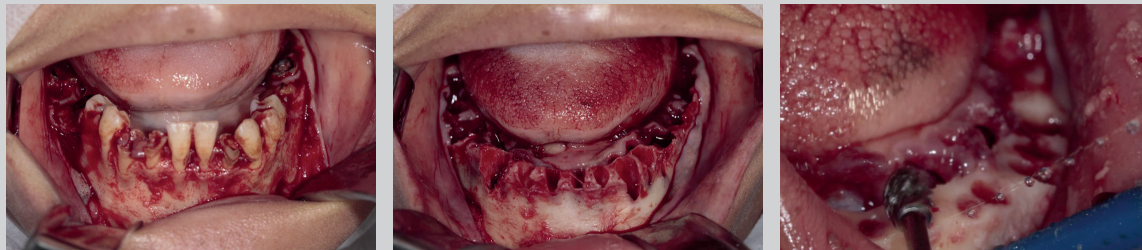
## STEP-BY-STEP OF THE PROCEDURE

*In the mandibular region, surgical access was performed with exposure of the bilateral mental foramina.*



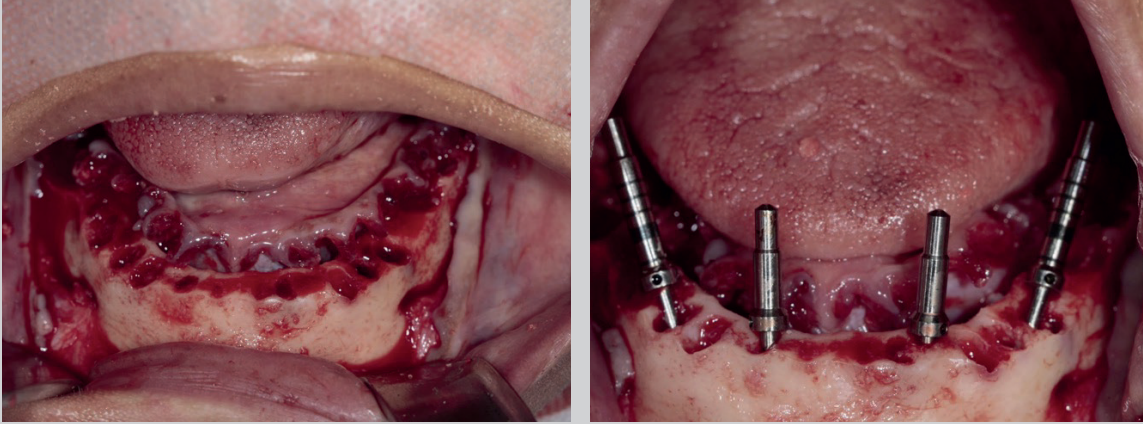
## STEP-BY-STEP OF THE PROCEDURE

*Extraction of the remaining teeth was performed, followed by alveolar ridge osteoplasty to prepare the site.*



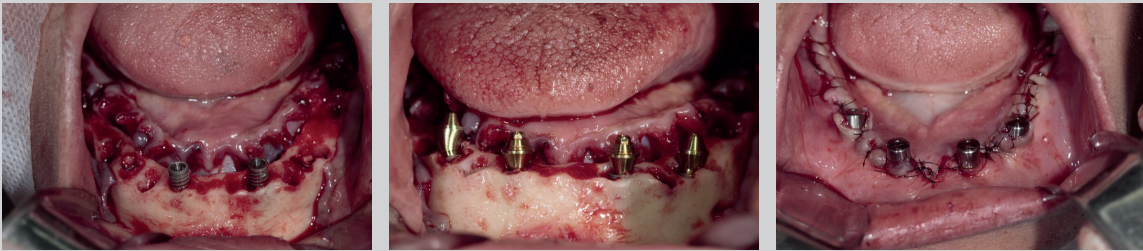
## INTRAOPERATIVE

*Implant drilling was performed, followed by position verification using direction indicators.*



## INTRAOPERATIVE

*Placement of 3.8 x 15 mm Strong SW Morse Taper implants and mini abutments, followed by suturing.*



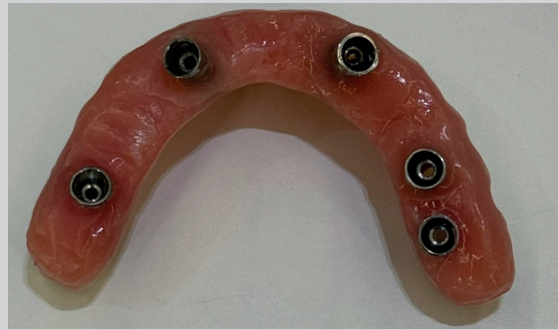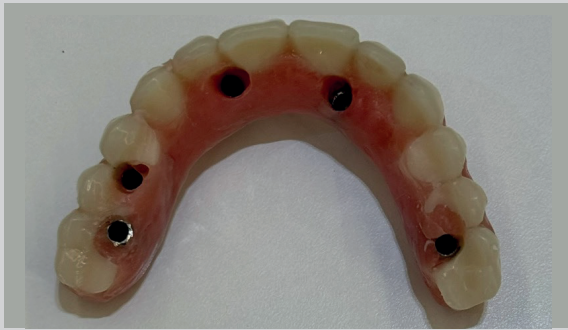## IMPLANTS USED

*Zygomatic Plus Implant / Epikut S PTG Plus Implant*



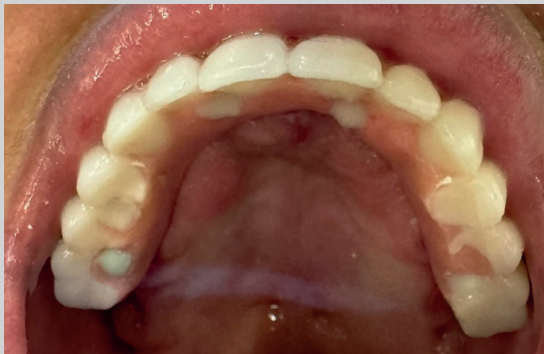## PROVISIONALIZATION

An acrylic prosthesis with a convex profile was fabricated to be installed over the implants.



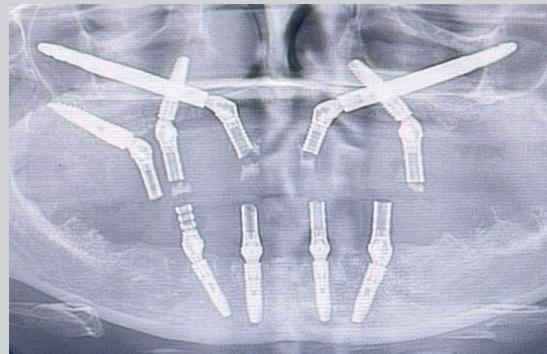
## PROSTHETIC PHASE

Temporary upper prosthesis installed 72 hours after the surgical procedure.



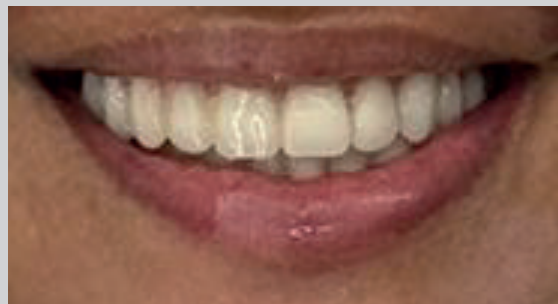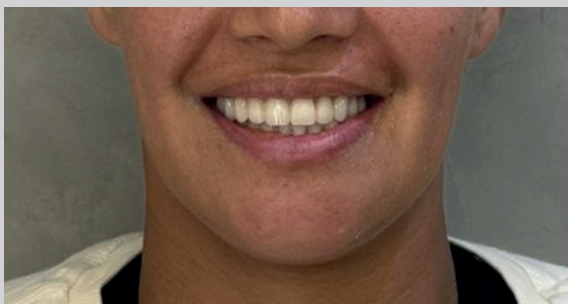## FINAL RADIOGRAPH

Postoperative panoramic radiograph.

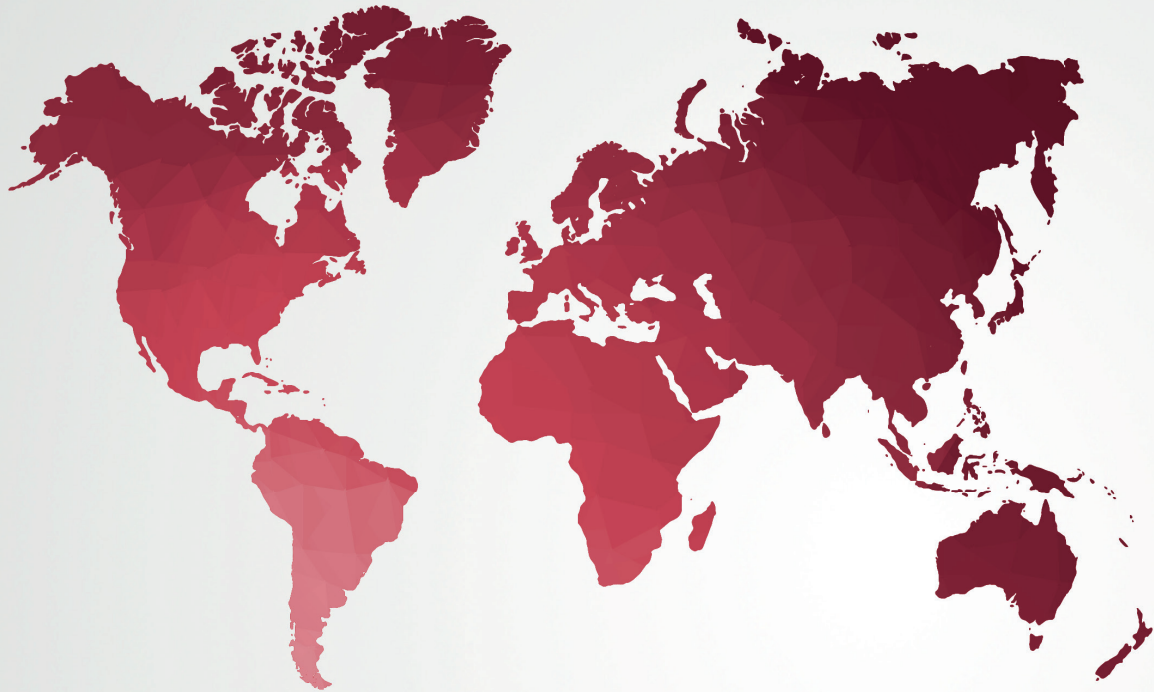


## FINAL RESULT

Extraoral image of the patient 15 days post-operation with provisional prostheses installed.



# OUR GLOBAL PRESENCE



POINT YOUR PHONE'S CAMERA AT THE  
QR CODE AND SEE WHERE S.I.N. IS PRESENT

## HEADQUARTERS

2140 Vereador Abel Ferreira Av  
Jardim Anália Franco  
São Paulo – SP - Brazil

## FACTORY

421 Soldado Ocimar Guimarães  
da Silva St - Jardim Anália Franco  
São Paulo – SP - Brazil

## PORTUGAL BRANCH

General Ferreira Martins St, 10 8D -  
1495-137 Algés - Portugal  
+351 21 412-0336

[sinimplantsystem.com](http://sinimplantsystem.com)

# SUPERIOR QUALITY AND TECHNOLOGY

*WE WARRANT, BECAUSE WE ARE PROUD OF OUR PRODUCTS.*



*S.I.N. main priority is assuring the quality and safety to our clients. Offering the best for implants, components, surgical kits and tooling is the base of all our action.*

## INSPECTION IN A 100% OF THE BATCHES MANUFACTURED

*The quality control is made in all S.I.N. products, to assure the success in the surgeries of all our clients, to meet the best quality standards, as well as to add value to all the ones who chose to give a smile back to people.*



**IMPLANTS WITH WARRANTY FOR LIFE\***



**5 YEARS OF WARRANTY PROSTHESIS COMPONENTS\***



**\*SCAN THE LATERAL QR CODE TO ACCESS S.I.N WARRANTY TERMS OR ACCESS THE LINK <https://go.sinimplantsystem.com/3SswnlE>**





Get to know Implantat, the educational streaming of S.I.N.

 [implantat.global](https://www.implantat.global)

[internacional@sinimplantsystem.com](mailto:internacional@sinimplantsystem.com)

[www.sinimplantsystem.com](https://www.sinimplantsystem.com)

---

Visit our social networks



[@sinimplantglobal](https://www.instagram.com/sinimplantglobal)



[@sinimplantglobal](https://www.facebook.com/sinimplantglobal)



[S.I.N. Implant System](https://www.youtube.com/S.I.N.ImplantSystem)



[/sin\\_implant](https://www.tiktok.com/sin_implant)