MANUAL

BEYOND Full Arch

S.I.N.

IMPLANTAT

EDUCATION POWERED BY S.I.N.

Discover IMPLANTAT, the educational habitat of S.I.N.
An online teaching platform created to make more professionals accelerate their career and increase their success.

Access
IMPLANTAT.GLOBAL
or scan the QR Code
and begin your journey
of knowledge now!

S.I.N.

SUMMARY

BEYOND FULL ARCH....4

IDENTIFYING THE PATIENT....6

COMPLETE PLANNING....8

TREATMENT GUIDELINES....9
- SURGICAL PLANNING....9
- AXIAL POSITIONING - 4 TO 8 IMPLANTS....9
- ANGLED POSITIONING - 4 TO 8 IMPLANTS....11

S.I.N. PRODUCTS....14

EPIKUT S....15
- EPIKUT S IMPLANTS....15
- INSTALLATION....16
- KIT....16
- MILLING....17

EPIKUT S LONG....19
- EPIKUT S LONG IMPLANTS....19
- INSTALLATION....20
- KIT....21
- PREPARATION....22
- MILLING....22

ZYGOMATIC....24
- ZYGOMATIC IMPLANTS....24
- INSTALLATION....26
- KIT....28
- MILLING....29

S.I.N. SOLUTIONS....32
- DIGITAL IMPRESSIONS....33
- INTRAORAL SCANNER....34
- PROSTHETIC REHABILITATION....35

CONSIDERATIONS ON THE FULL ARCH CONCEPT....36

SCIENTIFIC PUBLICATIONS....37

BEYOND
Full Arch



DARE TO GO BEYOND

Dare to go beyond is to offer your patients complete protocols that restore essential daily functions, such as eating and smiling, while boosting self-esteem and transforming lives, even in severe cases of maxillary atrophy.

Dare to go beyond, explore the art of Beyond Full Arch!

The total loss of natural teeth is typically seen in the elderly, requiring a rehabilitation that fully restores function and aesthetics. To meet these expectations precisely and reliably, **S.I.N.** presents **Beyond Full Arch**, which is based on a Decision Tree protocol. This protocol is suitable for patients with different degrees of bone resorption in the maxilla and mandible, whether mild, moderate, or severe.

The goal of this treatment is to restore both the smile and chewing function of patients.

The concept of full arch rehabilitation involves the use of various types of implants, varying in diameters, lengths, and techniques, to ensure the best personalized solution for each case.

In this manual, you will find all the **Beyond Full Arch** solutions that **S.I.N**. offers for different clinical indications.

IDENTIFYING THE PATIENT

Some preoperative exams may be necessary, including:

- Radiographic exam
- Cone Beam Computed Tomography (CBCT)
- 3D Software
- Surgical guides
- Reverse planning

Some measures are necessary to better identify a patient qualified for a full rehabilitation procedure, as well as to improve the treatment hierarchy:

› 01 Any medical conditions that could affect the patient's treatment outcome or their suitability for surgery should be considered. The patient's expectations should also be analyzed and documentede.

› 02 The patient's expectations and their history of implant failures should be analyzed, as well as any parafunctional habits, such as teeth grinding and bruxism.

› 03 The initial radiographic analysis with a panoramic X-ray is important. However, the professional should perform a computed tomography or a cone beam tomography. For full arch rehabilitation, this exam is mandatory for proper planning.

› 04 Evaluate the condition of the remaining teeth. In many cases, some teeth may need to be removed for prosthetic reasons. The evaluation should consider the state of periodontal health, untreatable focal infections, as well as the condition of the patient's soft tissues and mucosa. In the context of treatment longevity, mucosal conditions will be important.

› 05 The 3D planning software can be an essential and significant tool for better planning and achieving a better final result.

› 06 When clinically possible, the use of surgical guides and 3D planning using specialized software can be an important ally in improving results and accuracy.

› 07 Reverse planning: Ideally, all planning and surgical treatment should follow a proper prosthetic evaluation and pre-planning.

COMPLETE PLANNING

The complete arch planning should be entirely focused on the prosthesis. From this base, we begin an analysis of the quantity and quality of bone.

1 - Residual hard and soft tissues.

2 - Transition line: to determine aesthetic and prosthetic options.

3 - Evaluation of the patient's residual bone and degree of bone resorption: to determine surgical and prosthetic procedures.

4 - Digital planning:

3D models based on the patient's radiological data, along with radiographic guidance, allow the professional to assess the quality and quantity of available bone. Vital anatomical structures, such as the alveolar nerve and maxillary sinus, can also be marked, so that prosthetic planning can be carried out.

For a successful full rehabilitation, the initial prosthetic planning, built with the help of a tomographic guide and according to the correct occlusion using Cone Beam Computed Tomography (CBCT) images, will define the proper implant position, considering anatomical structures, especially for tilted posterior implants. If the patient already has a well-established conventional full denture, it can also be used as a guide and as an immediate provisional prosthesis supported by implants. Additionally, specialized planning software can be used to determine the position and angulation of the implants.

BONE RESORPTION PATTERNS

SEVERE RESORPTION

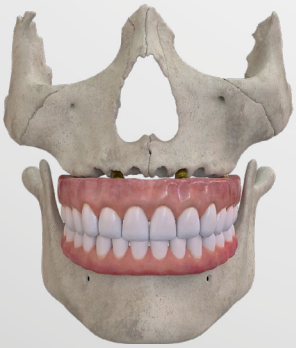

PARTIAL RESORPTION

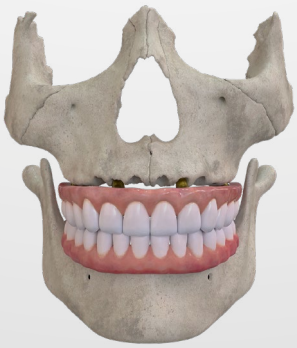

NORMAL VOLUME

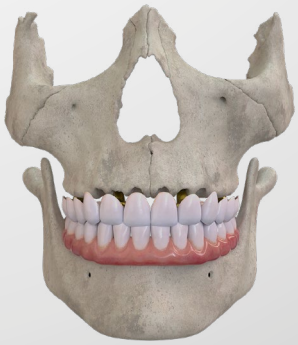

THE RESIDUAL ALVEOLAR BONE DIRECTS THE SURGICAL PROTOCOL.

TREATMENT GUIDELINES

Ideally, a full arch rehabilitation on implants should optimize immediate loading and implant installation with a minimum torque of 40N.cm. Once a full arch treatment plan has been developed and approved, the procedure and the full arch concept can be implemented.

SURGICAL PLANNING
AXIAL POSITIONING - 4 TO 8 IMPLANTS

In cases of skeletal class III, eight implants should be considered for installation in an axial or tilted position. In most cases, four to six implants are ideal.

Full arch with four implants.

Full arch with six implants.

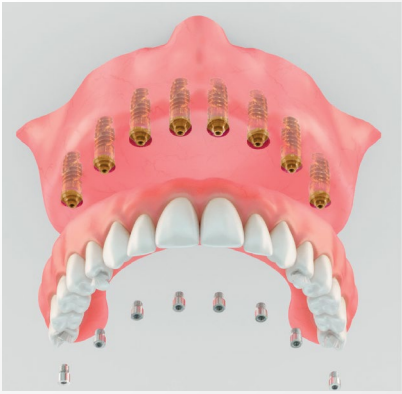

Full arch with eight implants.

• Clin Oral Implants Res. 1995 Dec;6(4):227-31.
Ten-year survival rates of fixed prostheses on four or six implants ad modum Brånemark in full edentulism.
Brånemark PI, Svensson B, van Steenberghe D.

• Implant Dent. 2015 Dec;24(6):680-5.
Stress Distribution in Bone and Implants in Mandibular 6-Implant-Supported Cantilevered Fixed Prosthesis: A 3D Finite Element Study.
Padhye OV, Herekar M, Patil V, Mulani S, Sethi M, Fernandes A.

UPPER ARCH

The distribution of implants should consider the shape and size of the maxillary sinus and regions with less available bone.

Make an incision that allows full access to the alveolar ridge, followed by a full flap. In case of tooth extractions, careful curettage of the socket is required, as well as the creation of a bone plateau for implant placement. The transition of the smile line and lip support should be considered.

Implants should be installed axially in the anatomical positions of the central incisor, the canine, the first premolar, and the first molar. Anterior implants should be placed palatally, and the installation of implants at 45° angle posteriorly should be considered, depending on the patient's anatomy. Distal cantilevers beyond one tooth and severe parafunction should be avoided. For immediate loading, a primary implant stability of > 45Ncm is recommended. In areas of tooth extraction, implants should preferably be placed in the interalveolar regions.

Installation of straight anterior implants (maxilla).

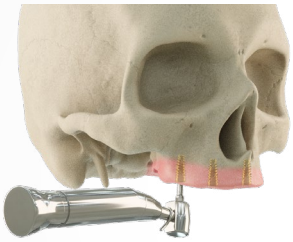

Installation of posterior implants (maxilla).

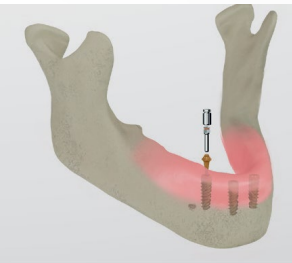

Installation of straight abutments (maxilla).

Instalação de abutments retos (maxila).

LOWER ARCH

The distribution of implants should consider the position and distance of the inferior alveolar and mental nerves.

Make an incision allowing full access to the alveolar ridge, followed by a full flap. In the case of tooth extractions, careful curettage of the socket is required, as well as the creation of a bone plateau for implant placement. The transition of the smile line and lip support should be considered, as well as the location of the mental foramen, which will be the distal limit of the implants, especially if there is insufficient bone height in the posterior regions of the mandible.

Implants should be installed axially in the anatomical positions of the central incisor, the canine, the first premolar, and the first molar. Anterior implants should be placed lingually, and the installation of posterior implants with an inclination of 45 degrees should be considered, depending on the patient's anatomy. Distal cantilevers beyond one tooth and severe parafunction should be avoided. For immediate loading, a primary implant stability of >45N.cm is recommended. In extraction areas, implants should preferably be placed in the interalveolar regions.

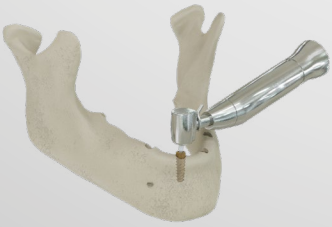

Installation of straight anterior implants (mandible).

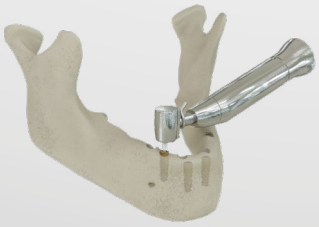

Installation of posterior implants.

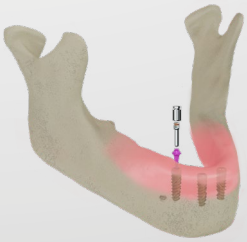

Installation of straight abutments (mandible).

Full arch, fully installed (mandible).

ANGLED POSITIONING - 4 TO 8 IMPLANTS

Four implants (tilted distal implants)

To treat cases with a high degree of bone resorption, it is possible to use four implants: two anterior axial implants and two posterior implants tilted up to 45°.

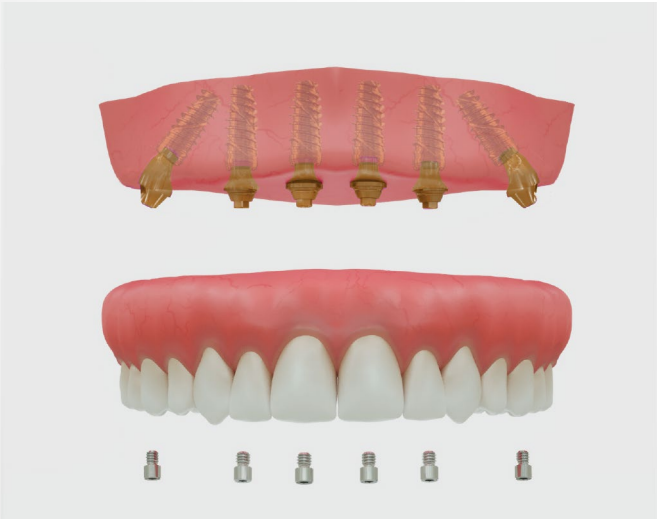

Six implants (tilted distal implants)

The inclination of the two posterior implants improves the bone-implant contact and provides excellent bone support, even with minimal bone volume. A surgical guide, considering the patient's anatomy, can be used if necessary.

• Clin Implant Dent Relat Res 2018 Oct;20(5):867-874
Implant rehabilitation of the edentulous jaws: Does tilting of posterior implants at an angle greater than 45 affect bone resorption and implant success?: A retrospective study.
Malchiodi L, Moro T, Cattina DP, Cucchi A, Ghensi P, Nocini PF

• J Oral Maxillofac Surg 1999; 57(3):281-287
Implant treatment without bone grafting in severely resorbed edentulous maxillae.
Mattsson T, Köndell PA, Gynther GW, Fredholm U, Bolin A

• Int J Oral Maxillofac Implants 2009 May-Jun;24(3):527-33
Palatal Positioning of Implants in Severely Resorbed Edentulous Maxillae.
Peñarrocha M, Carrillo C, Boronat A, Balaguer J, Peñarrocha M

• Clin Implant Dent Relat Res. 2005;7 Suppl 1:S88-94
All-on-4 immediate-function concept with Brånemark System implants for completely edentulous maxillae: a 1-year retrospective clinical study.
Maló P., Rangert B., Nobre M.

• Clin Implant Dent Relat Res. 2014 Dec;16(6):836-55
The all-on-four treatment concept: a systematic review.
Patzelt SB, Bahat O, Reynolds MA, Strub JR.

• J Prosthodont Res. 2017 Apr;61(2):123-132.
Biomechanical analysis of immediately loaded implants according to the "All-on-Four" concept.
Horita S, Sugiura T, Yamamoto K, Murakami K, Imai Y, Kirita T.

• Int J Oral Maxillofac Implants 2016;31:1017–1022. (Portuguese Edition)
Nova Proposta Para Reabilitação de Maxila Atrófica: Implante Inclinado LONG.
Marcelo de Carvalho, Liliane Pacheco de Carvalho, Rogerio de Lima Romeiro, Carlos Eduardo Francischone, Bruno Salles Sotto-Maior, Fabio Bezerra

• Compend Contin Educ Dent. 2016;37(7):458–465
All-on-4® Implant Treatment: Common Pitfalls and Methods to Overcome Them.

UPPER ARCH

The distribution of implants should consider the shape and size of the maxillary sinus and regions with less bone availability.

Make an incision allowing full access to the alveolar crest, followed by a full flap. In case of tooth extractions, careful curettage of the socket is required, as well as the creation of a bone plateau for implant placement. The transition of the smile line and lip support should be considered.

Two to four anterior implants should be installed in the palatal position, and two posterior implants with an inclination of up to 45°.

The inclination of the two posterior implants improves bone-implant contact and provides excellent bone support even with low bone volume, as it allows the use of longer implants, as well as bicorticalization. Additionally, the inclination of the implants in the maxilla provides better anchorage to the anterior bone of higher quality.

Bicortical anchorage to the cortical bone of the sinus wall and the nasal fossa can also be considered. Distal cantilevers beyond one tooth and severe parafunctions should be avoided.

For immediate loading, a primary implant stability of >45Ncm is recommended. In extraction areas, implants should be placed between the extraction sockets.

PROSTHESIS (6 IMPLANTS)

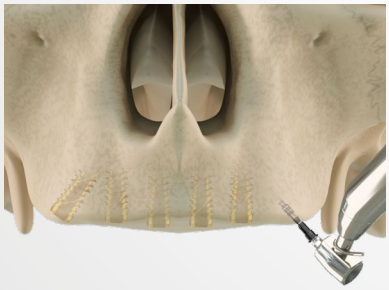

Installation of angled implants

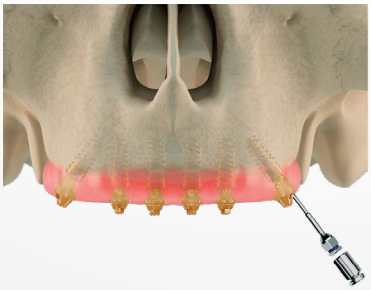

Installation of angled abutments

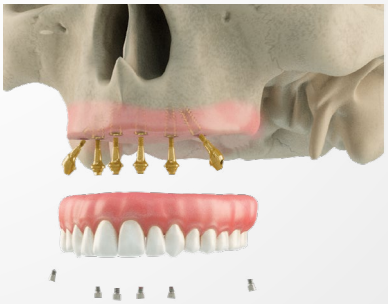

Implants and prosthesis.

PROSTHESIS (4 IMPLANTS)

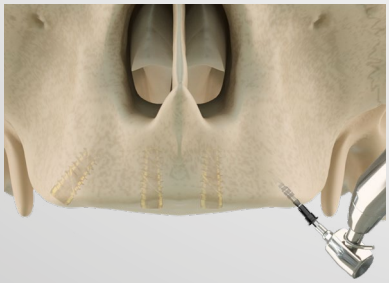

Installation of angled implants

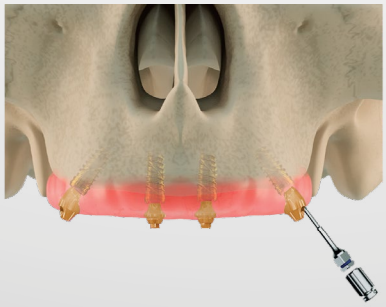

Installation of angled abutments

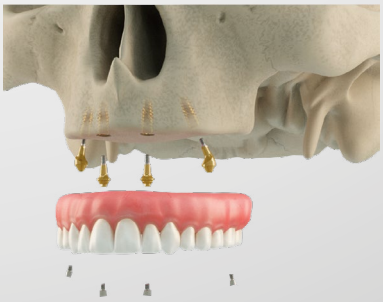

Implants and prosthesis.

LOWER ARCH

The distribution of implants should consider the position and extension of the inferior alveolar and mental nerves.

Make an incision allowing full access to the alveolar ridge, followed by a full-thickness flap. In case of dental extractions, careful curettage of the socket is necessary, as well as the creation of an osseous plateau for implant insertion. Lip support should be considered.

For fixed prostheses, two axial implants should be placed near the midline, along with two distal implants with an inclination of no more than 45º. This allows for screw exit and positioning of the prosthetic abutment closer to the first lower molar region, reducing the prosthetic lever arm.

For immediate loading, an implant primary stability of >45Ncm is recommended. In extraction sites, implants should be placed between the extraction sockets.

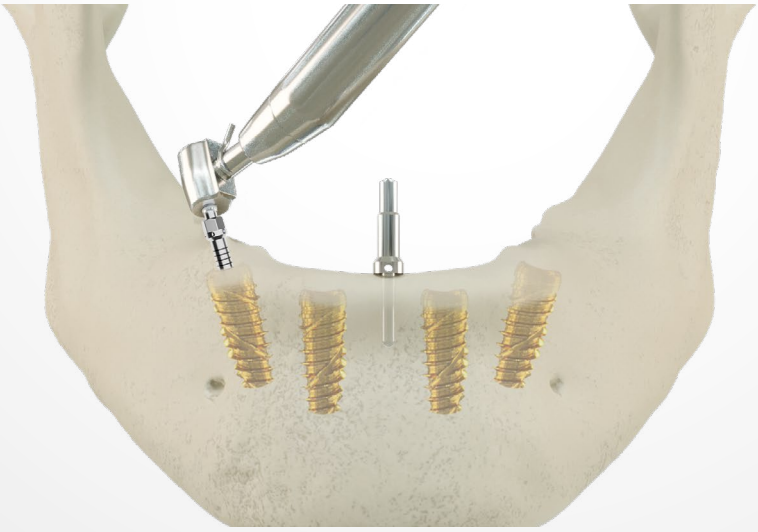

Implants positioned for full rehabilitation (inclined distals)

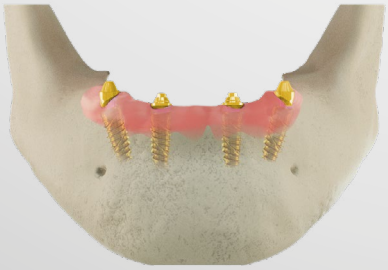

Abutments.

Implants and prosthesis.

PRODUCTS S.I.N.

The S.I.N. Implant System offers various implant lines that make the daily practice of professionals easier for surgical procedures. Through Beyond Full Arch, we have the Epikut S line, with conventional implant sizes, and the Epikut S Long line, which includes longer sizes, reaching up to 24 mm. There is also the Zygomatic Plus line, which features a 16° connection.Below, we will discuss the details of each line.

EPIKUT S

THE IMPLANTS

The Epikut S implants are made of commercially pure, biocompatible titanium (Grade IV cold worked) and are available with only the surface treatment of dual acid etching (DAA) or with the DAA treatment followed by the application of nanometric thickness hydroxyapatite (HAnano).

The exclusive macrogeometry featuring progressive cutting threads makes the Epikut the state-of-the-art choice for immediate load cases, low-density bone, and post-extraction sockets. Extremely versatile, the Epikut S can also be used in other clinical situations as long as the recommended clinical drilling protocol is followed. Its finer apex, with a diameter of 2 mm, facilitates bicorticalization.

The Epikut S line has a 16° Cone Morse connection (MT 16°), with lengths of 8.5, 10, 11.5, 13, and 15 mm, and diameters of 3.5, 3.8, 4.0, 4.5, and 5.0, as described in the table below:

TECHNICAL MEASUREMENTS				
		A	B	C
DAA CODE	PLUS CODE	PLATFORM DIAMETER (mm)	APICAL DIAMETER (mm)	LENGTH (mm)
ILM 3585	ILM 3585N	3,5	2,0	8,5
ILM 3510	ILM 3510N			10,0
ILM 3511	ILM 3511N			11,5
ILM 3513	ILM 3513N			13,0
ILM 3515	ILM 3515N			15,0
ILM 3885	ILM 3885N	3,8	2,0	8,5
ILM 3810	ILM 3810N			10,0
ILM 3811	ILM 3811N			11,5
ILM 3813	ILM 3813N			13,0
ILM 3815	ILM 3815N			15,0
ILM 4085	ILM 4085N	4,0	2,0	8,5
ILM 4010	ILM 4010N			10,0
ILM 4011	ILM 4011N			11,5
ILM 4013	ILM 4013N			13,0
ILM 4015	ILM 4015N			15,0
ILM 4585	ILM 4585N	4,5	2,95	8,5
ILM 4510	ILM 4510N			10,0
ILM 4511	ILM 4511N			11,5
ILM 4513	ILM 4513N			13,0
ILM 4515	ILM 4515N			15,0
ILM 5085	ILM 5085N	5,0	2,95	8,5
ILM 5010	ILM 5010N			10,0
ILM 5011	ILM 5011N			11,5
ILM 5013	ILM 5013N			13,0
ILM 5015	ILM 5015N			15,0

INSTALLATION

The placement of conventional size implants from the Epikut S line follows a technical approach that prioritizes stability and bone integration. These implants are designed with dimensions that promote anchorage in native bone, reducing the need for grafts and facilitating installation in regions of high-quality bone.

KIT

For the installation of Epikut implants, it is necessary to use the specific kit for this line. A complete and compact kit with a linear and intuitive sequence.

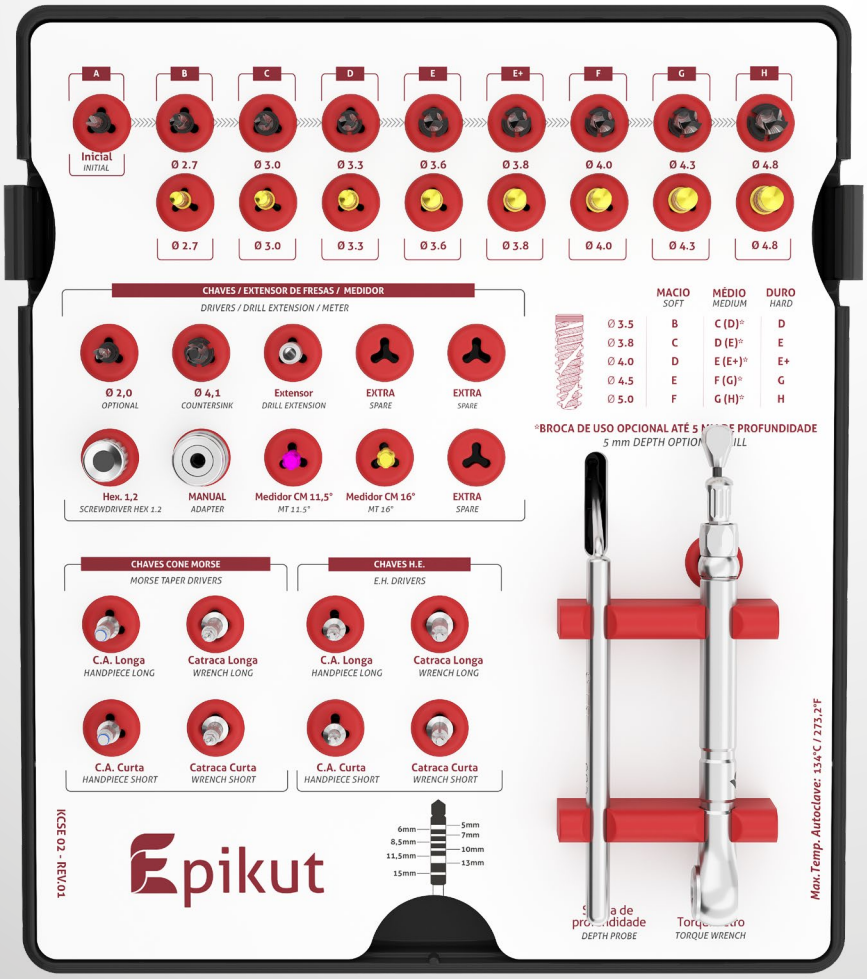

CODE	DESCRIPTION
FL 20	LAUNCH DRILL Ø2,0MM
FHE 27	CONICAL DRILL Ø2,7MM
FHE 30	CONICAL DRILL Ø 3,0MM
FHE 33	CONICAL DRILL Ø 3,3MM
FHI 36	CONICAL DRILL Ø 3,6MM
FHI 38	CONICAL DRILL Ø 3,8MM
FHI 40	CONICAL DRILL Ø 4,0MM
FHI 43	CONICAL DRILL Ø 4,3MM
FHI 48	CONICAL DRILL Ø 4,8MM
ID 2720L	DIRECTION INDICATOR Ø2,7xØ2,0MM LONG
ID 3020L	DIRECTION INDICATOR Ø3,0xØ2,0MM LONG
ID 3320L	DIRECTION INDICATOR Ø3,3xØ2,0MM LONG
ID 3620L	DIRECTION INDICATOR Ø3,6xØ2,0MM LONG
ID 3820L	DIRECTION INDICATOR Ø3,8x Ø2,0MM LONG
ID 4020L	DIRECTION INDICATOR Ø4,0xØ2,0MM LONG
ID 4320L	DIRECTION INDICATOR Ø4,3xØ2,0MM LONG
ID 4820L	DIRECTION INDICATOR Ø4,8xØ2,0MM LONG

CODE	DESCRIPTION
FH 20	HELICOIDAL DRILL Ø2,0MM
FC 41	COUNTERSINK DRILL Ø4,1MM
EXFN	EXTENSION KEY FOR DRILL
CDH 1224	DIGITAL HEX 1.2 MEDIUM KEY
CBD 01	BI-DIGITAL KEY
MTCM 11	TRANSMUCOSAL GAUGE CM 11,5°
MTCM 16	TRANSMUCOSAL GAUGE MT 16°
CTMD 24	CONTRA-ANGLE KEY FOR IMPLANT CM LONG
CTMD 20	CONTRA-ANGLE KEY FOR IMPLANT CM SHORT
CCM 24	RATCHET KEY FOR IMPLANT CM LONG
CCM 20	RATCHET KEY FOR IMPLANT CM SHORT
CTWD 24	CONTRA-ANGLE KEY FOR IMPLANT HE LONG
CTWD 20	CONTRA-ANGLE KEY FOR IMPLANT HE SHORT
CCW 24	RATCHET KEY FOR IMPLANT HE LONG
CCW 20	RATCHET KEY FOR IMPLANT HE SHORT
SOP 20	DEPTH PROBE
TMECC 02	SURGICAL TORQUE WRENCH

MILLING

FOR BONE SOFT TYPE

Drilling sequence used for type IV bone.

Epikut S Epikut S Plus

		1.200 RPM	800 RPM							
	Ø DIÂM. (mm)	FL 20 (A)	FHE 27 (B)	FHE 30 (C)	FHE 33 (D)	FHI 36 (E)	FHI 38 (E+)	FHI 40 (F)	FHI 43 (G)	FHI 48 (H)
ILM35xx	3,5	•	•							
ILM38xx	3,8	•	•	•						
ILM40xx	4,0	•	•	•	•					
ILM45xx	4,5	•	•	•	•	•				
ILM50xx	5,0	•	•	•	•	•	•	•		

FOR BONE MEDIUM TYPE

Drilling sequence used for type II and III bone.

Epikut Epikut S Plus

		1.200 RPM	800 RPM							
	Ø DIÂM. (mm)	FL 20 (A)	FHE 27 (B)	FHE 30 (C)	FHE 33 (D)	FHI 36 (E)	FHI 38 (E+)	FHI 40 (F)	FHI 43 (G)	FHI 48 (H)
ILM35xx	3,5	●	●	●	○					
ILM38xx	3,8	●	●	●	●	○				
ILM40xx	4,0	●	●	●	●	●	○			
ILM45xx	4,5	●	●	●	●	●	●	●	○	
ILM50xx	5,0	●	●	●	●	●	●	●	●	○

● Use of the optional countersink drill at a depth of 5.0 mm.

FOR BONE HARD TYPE

Drilling sequence used for type I bone.

Epikut S Epikut S Plus

		1.200 RPM	800 RPM							
	Ø DIÂM. (mm)	FL 20 (A)	FHE 27 (B)	FHE 30 (C)	FHE 33 (D)	FHI 36 (E)	FHI 38 (E+)	FHI 40 (F)	FHI 43 (G)	FHI 48 (H)
ILM35xx	3,5	●	●	●	●					
ILM38xx	3,8	●	●	●	●	●				
ILM40xx	4,0	●	●	●	●	●	●			
ILM45xx	4,5	●	●	●	●	●	●	●	●	
ILM50xx	5,0	●	●	●	●	●	●	●	●	●

EPIKUT S LONG

THE IMPLANTS

The Epikut S Long implants are made of commercially pure, biocompatible titanium (Grade IV cold worked) and have a surface treatment of dual acid etching (DAA) followed by the application of nanometric layer hydroxyapatite (HAnano).

They are exclusively indicated for multiple rehabilitations in fully edentulous maxillae. These implants can be combined with conventional, pterygoid, and/or zygomatic implants.

According to the complete arch rehabilitation technique, at least four implants should be distributed in the maxilla to retain the full prosthesis.

The Epikut S Long line features a 16° Cone Morse connection (MT 16°), with lengths of 18, 20, 22, and 24 mm, and diameters of 3.8, 4.0, and 4.5, as described in the table below:

TECHNICAL MEASUREMENTS				
		A	B	C
CODE DAA	CODE PLUS	PLATFORM DIAMETER (mm)	APICAL DIAMETER (mm)	LENGTH (mm)
ILM 3818	ILM 3818N	3,8	2,0	18
ILM 3820	ILM 3820N			20
ILM 3822	ILM 3822N			22
ILM 3824	ILM 3824N			24
ILM 4018	ILM 4018N	4,0	2,0	18
ILM 4020	ILM 4020N			20
ILM 4022	ILM 4022N			22
ILM 4024	ILM 4024N			24
ILM 4518	ILM 4518N	4,5	2,95	18
ILM 4520	ILM 4520N			20
ILM 4522	ILM 4522N			22
ILM 4524	ILM 4524N			24



INSTALLATION

The technical approach for placing long implants is similar to that of conventional-sized implants. The Epikut S Long implants have dimensions and lengths that provide excellent bone anchorage. Additionally, placing the implants in the patient's native bone helps avoid bone grafts and facilitates implant placement in regions of excellent bone quality.

The tangential approach to the maxillary sinus, with the placement of inclined implants in the canine pillar region, utilizing the entire available bone height, allows for high torques and, consequently, the use of the immediate load technique.

Four implants are used: two posterior and two anterior. The two posterior implants are placed in the position of the premolars, with an inclined direction up to a maximum of 45º, in a mesial direction tangent to the anterior wall of the maxillary sinus, with the prosthetic platform emerging in the position of the second premolar or first molar. The two anterior implants can be placed straight or inclined.

The maximum torque for installing the Epikut S Long, without causing damage or fractures, is 80 N/cm.

Thus, the Epikut S Long line allows for the rehabilitation of edentulous patients in a simpler, faster, and more predictable manner.

KIT

For the installation of Epikut S Long implants, it is necessary to use the specific kit for this line. It is a complete and compact kit with a linear and intuitive sequence. It features angled direction indicators divided by colors, a more modern system that facilitates its clinical use.



CODE	DESCRIPTION
FL 2024	HELICOIDAL DRILL Ø 2,0 X 24MM
FHE 2324	CONICAL DRILL Ø 2,35 X 24MM
FHE 3024	CONICAL DRILL Ø 3,0 X 24MM
FHI 3324	CONICAL DRILL Ø 3,3 X 24MM
FHI 3624	CONICAL DRILL Ø 3,6 X 24MM
FHI 3824	CONICAL DRILL Ø 3,8 X 24MM
FHI 4024	CONICAL DRILL Ø 4,0 X 24MM
FHI 4324	CONICAL DRILL Ø 4,3 X 24MM
CTMD 20	CONTRA-ANGLE KEY FOR IMPLANT CM SHORT
CTMD 24	CONTRA-ANGLE KEY FOR IMPLANT CM LONG
CCM 20	RATCHET KEY FOR IMPLANT CM SHORT
CCM 24	RATCHET KEY FOR IMPLANT CM LONG
IDA 17	DIRECTION INDICATOR ANGULADO 17°
IDA 30	DIRECTION INDICATOR ANGULADO 30°
IDA 45	DIRECTION INDICATOR ANGULADO 45°
CBD 01	BI-DIGITAL KEY
CDH 1220	DIGITAL HEX 1.2 SHORT
TMECC 02	SURGICAL TORQUE WRENCH
SOPL 01	DEPTH PROBE LONG

PREPARATION

After the installation of Epikut S Long implants, proceed with the selection of abutments, provisional prosthetic rehabilitation, and fabrication of the final prosthesis. This step is no different from the technique used with conventional implants.

MILLING

The use of long implants is indicated to achieve good anchorage in areas with better bone density, such as the canine pillar area and the lateral wall of the nasal cavity. The planning is based on the principles that guide all rehabilitations: clinical study of radiographic and tomographic exams, laboratory tests, digital photographs, obtaining plaster models, mounting on a semi-adjustable articulator, and creating a surgical guide through reverse planning. This planning can also be done digitally, so that the implant installation can be simulated using software and prototypes.

FOR BONE SOFT TYPE

Drilling sequence used for type IV bone.

Epikut S Longo | Epikut S Longo Plus

		1.200 RPM	800 RPM						
	Ø DIÂM. (mm)	FL 2024 (A)	FHE 2324 (B)	FHE 3024 (C)	FHI 3324 (D)	FHI 3624 (E)	FHI 3824 (E+)	FHI 4024 (F)	FHI 4324 (G)
ILM38xx	3,8	•	•	•					
ILM40xx	4,0	•	•	•	•				
ILM45xx	4,5	•	•	•	•	•			

FOR BONE MEDIUM TYPE

Drilling sequence used for type II and III bone.

Epikut S Longo

Epikut S Longo Plus

		1.200 RPM	800 RPM						
	Ø DIÂM. (mm)	FL 2024 (A)	FHE 2324 (B)	FHE 3024 (C)	FHI 3324 (D)	FHI 3624 (E)	FHI 3824 (E+)	FHI 4024 (F)	FHI 4324 (G)
ILM38xx	3,8	●	●	●	●	○			
ILM40xx	4,0	●	●	●	●	●	○		
ILM45xx	4,5	●	●	●	●	●	●	●	○

○ Use of the drill is optional.

FOR BONE HARD TYPE

Drilling sequence used for type I bone.

Epikut S Longo

Epikut S Longo Plus

		1.200 RPM	800 RPM						
	Ø DIÂM. (mm)	FL 2024 (A)	FHE 2324 (B)	FHE 3024 (C)	FHI 3324 (D)	FHI 3624 (E)	FHI 3824 (E+)	FHI 4024 (F)	FHI 4324 (G)
ILM38xx	3,8	●	●	●	●	●			
ILM40xx	4,0	●	●	●	●	●	●		
ILM45xx	4,5	●	●	●	●	●	●	●	●

ZYGOMATIC PLUS

THE IMPLANTS

Zygomatic Plus implants are manufactured from Grade IV Cold Worked titanium and feature a dual acid-etching (DAA) surface treatment followed by the application of nano-hydroxyapatite (HAnano) in the threaded area, while the cervical area is treated only with HAnano without prior DAA.

Their insertion is performed using a carrier wrench for a contra-angle, which is provided in the specific surgical kit for this line. Installation is completed with a specific wrench for the Zygomatic implant, which can be attached to a hand wrench and/or torque wrench.

Zygomatic Plus implants must be placed in the upper maxillary arch to provide support for fixed dental prostheses in patients with fully edentulous maxillae. The Zygomatic Plus implant by S.I.N. has both threaded and non-threaded sections. The threaded portion of the implant, measuring 17.10 mm, is located in its apical part and is designed to provide anchorage in the patient's zygomatic bone. The surgeon should expect high-density bone in this area.

The smooth, non-threaded surface is intended to achieve passive stability over the alveolar process with a press-fit insertion into surgical sockets or resting against the bone, depending on the chosen technique. All implants are suitable for immediate loading when good primary stability is achieved and with appropriate occlusal loading.

The Zygomatic Plus line features a 16° Cone Morse connection (MT 16°) and comes in lengths of 30; 32.5; 35; 37.5; 40; 42.5; 45; 47.5; 50; 52.5; 55; 57.5; 60; and 62.5 mm, with a diameter of 4.0 mm, as detailed in the table below:

TECHNICAL MEASUREMENTS			
	A	B	C
CODE	PLATFORM DIAMETER (mm)	APICAL DIAMETER (mm)	LENGTH (mm)
ILMZ 4030N	Ø4,0	Ø2,0	30,0
ILMZ 4032N	Ø4,0	Ø2,0	32,5
ILMZ 4035N	Ø4,0	Ø2,0	35,0
ILMZ 4037N	Ø4,0	Ø4,0	37,5
ILMZ 4040N	Ø4,0	Ø2,0	40,0
ILMZ 4042N	Ø4,0	Ø2,0	42,5
ILMZ 4045N	Ø4,0	Ø2,0	45,0
ILMZ 4047N	Ø4,0	Ø2,0	47,5
ILMZ 4050N	Ø4,0	Ø2,0	50,0
ILMZ 4052N	Ø4,0	Ø2,0	52,5
ILMZ 4055N	Ø4,0	Ø2,0	55,0
ILMZ 4057N	Ø4,0	Ø2,0	57,5
ILMZ 4060N	Ø4,0	Ø2,0	60,0
ILMZ 4062N	Ø4,0	Ø2,0	62,5

INSTALLATION

In severely resorbed maxillae, Zygomatic Plus implants are placed along with two or four conventional anterior implants. The Zygomatic Plus implants are anchored in the zygomatic bone. Typically, the prosthetic platform of the implant emerges slightly in the palatal position between the second premolar and the first upper molar region.

Two to four anterior implants should be installed axially in the palatal position, and two zygomatic implants should be tilted to provide an optimal prosthetic emergence, preferably at the center of the alveolus.

A 45° palatal incision along the entire bone crest, combined with a full-thickness flap from the maxillary crest to the zygomatic bone support and the identification of the infraorbital nerve, are the first steps of this surgery.

For the surgical procedure, if the patient has a complete lower denture, its removal may help manage the typically long instruments required for the placement of zygomatic implants.

Different drills with increasing diameters are used, concluding with the insertion of the ultra-threaded zygomatic implant at low speed. The implant length is selected using a probe and can range from 30.0 mm to 62.5 mm.

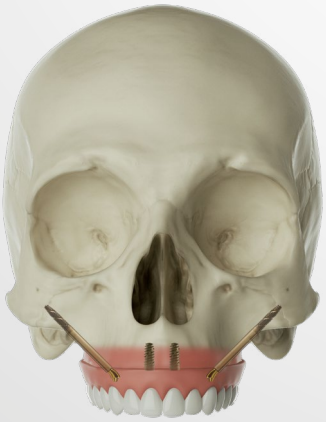

Example of insertion of Zygomatic Plus implant associated with anterior implants.

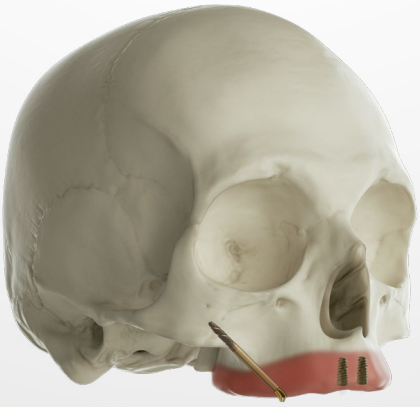

Detail of the Zygomatic Plus implant and its anatomical relationship with the ocular cavity.

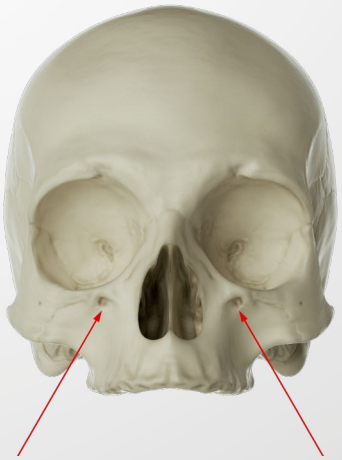

Infraorbital foramen.

The technique for installation can be the one recommended by Branemark, with intrasinusal drilling, the Slot technique, where access and detachment of the maxillary sinus membrane are performed, or the exteriorized technique, where the implant will touch the wall of the maxillary sinus.

The most posterior implant is installed first; the palatine entry is made in the molar region, with the implant passing slightly behind the support and drilling the zygomatic bone from the medial face. The entry into the zygoma should be low and posterior, and the soft tissues should be carefully retracted. It is important to use sharp helical burs to avoid surgical accidents, as well as overheating.

The second implant is installed in the premolar region, following the lower zygomatic crest into the sinus and drilling the medial part of the zygomatic bone.

Ideally, each implant should be supported by the surrounding bone, both at the neck and at the apex. Often, the bone in the crest is very thin, so it is easy to create an entry hole larger than the implant. In patients with very severe resorption, the entry is sometimes located in the compact palatine bone. Therefore, it is important that the palatine hole and the zygoma hole have exactly the same direction to avoid stresses and difficulties during implant installation.

The maximum torque for installing the Zygomatic Plus, without causing damage or fractures, is 80 N/cm.

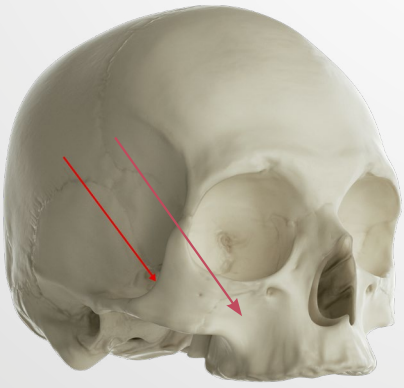

Posterior margin of the zygomatic bone.

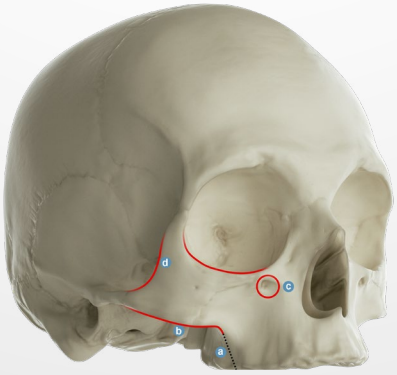

Anatomical references to protect the orbital cavity from injuries.

Viewing window.

KIT

For the installation of Zygomatic implants, it is necessary to use the specific kit for this line. A complete and compact kit with a linear and intuitive sequence.



CODE	DESCRIPTION
FRLZ 27	LAUNCH DRILL Ø2.35MM
FHZ 2030	HELICOIDAL DRILL PILOTO Ø2.75MM
FHZ 2932	HELICOIDAL DRILL Ø3.0MM
FHZ 3234	HELICOIDAL DRILL Ø3.2MM
FBD 40	DIAMOND DRILL Ø4,0X40MM GROSSA
FBD 40E	SPHERICAL DIAMOND DRILL Ø4,0MM
CQCA 27	COUNTER ANGLE WRENCH 4.0MM
CTHA 1224	COUNTER ANGLE WRENCH HEX.1.2MM EST. MEDIUM
FL 20M	LAUNCH DRILL Ø2.0MM MEDIA
CCM 01L	RATCHET KEY FOR IMPLANT CM LONG
CCM 01M	RATCHET KEY FOR IMPLANT CM MEDIUM
CDH 1224	DIGITAL WRENCH HEX 1.2 MEDIUM
CMZ	WRENCH FOR ZYGOMATIC IMPLANT
SOPZ	ZYGOMATIC DEPTH PROBE

Check product availability in your country

MILLING

For implant installation, the following milling sequence should be followed.



CODE	REFERÊNCIA
FRLZ 27M	LAUNCH DRILL Ø2.35MM MEDIUM
FHZ 2030M	HELICOIDAL DRILL PILOTO Ø2.75MM MEDIUM
FHZ 2932M	HELICOIDAL DRILL Ø3.0MM MEDIUM
FHZ 3234M	HELICOIDAL DRILL Ø3.2MM MEDIUM

**The Launch and Helical Burs (A, B, C, and D) are also available in a short option to facilitate milling in specific cases. This version is sold separately.*

PROSTHETIC PLANNING

Angled abutments are recommended for tilted posterior implants. Install the mini-abutment with a torque of 20 N.cm using the Hex 1.2 wrench from the S.I.N. prosthetic kit.

The recommendation for axially installed implants is to use a straight mini-abutment with a torque of 20 N.cm using the wrench specifically for mini-abutments.

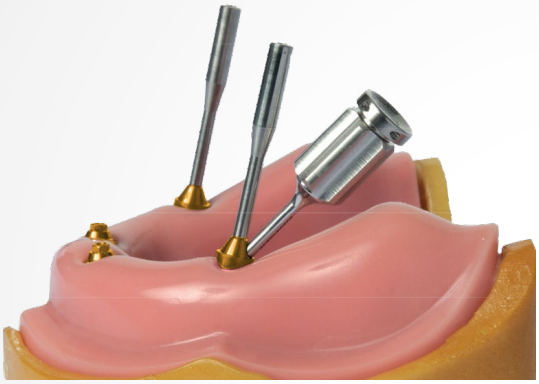

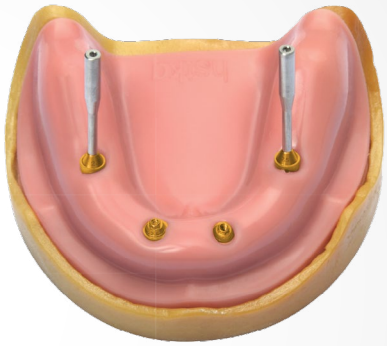

CONVENTIONAL REHABILITATION (ANALOGUE)

Precisely place the impression transfer of the mini abutment onto the component and only tighten the screw manually or with the help of a 1.2 hexagonal wrench.

For taking the impression, it is recommended to use a standard elastomeric impression material (e.g., polyvinylsiloxane).

When the impression is ready, place the analogs and send the impression to the prosthetic laboratory. This final gypsum model will be used in the next steps of the rehabilitation process.

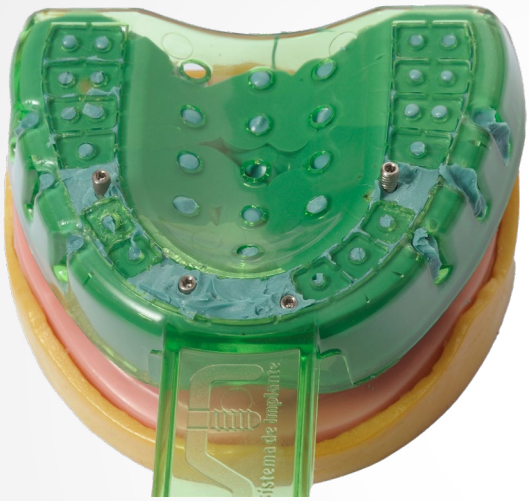

Wax the structure of the bar according to the available interocclusal space of the patient.

Place the bar and check its alignment with the model. Produce the final prosthesis based on the previously verified bar.

Install the definitive fixed prosthesis. Check that the final torque of the cylinder screws is 10 N.cm.

Check and adjust the correct occlusion.

S.I.N. SOLUTIONS

The digital workflow is the sequence of steps necessary to automate processes, based on a well-defined set of rules that allow its transmission from one person to another.

Thanks to technological advancements, lower costs, and greater dissemination, more and more professionals are able to work with the digital workflow.

The digital workflow consists of an intraoral image, an impression, a model, or a digital wax-up to obtain a virtual model and enable planning and preparation of rehabilitation in computer software (CAD).

The software files are sent to a milling machine that produces or materializes the corresponding files (CAM).

STL stands for stereolithography. The format of an STL file uses a series of interconnected triangles to recreate the geometry of the solid model.

Due to the contrast achieved, colored scanning can help identify the tooth color and the finish line of the tooth preparation. Virtual models can also be used for complex prosthetic rehabilitations, orthodontic planning, osteotomies, surgical guides, and guided surgery.

• J Prosthet Dent. 2019 feb;121(2):246-251
Accuracy of digital technologies for the scanning of facial, skeletal, and intraoral tissues: a systematic review.
Bohner L, Gamba DD, Hanisch M, Marcio BS, Tortamano Neto P, Laganá DC, Sesma N.

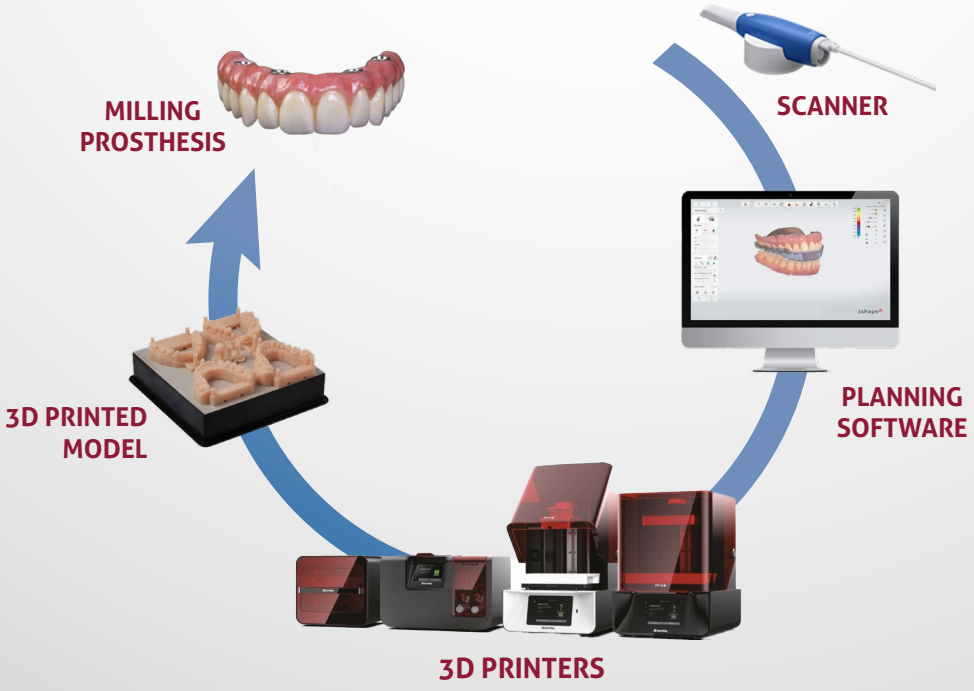

www.medicalexpo.com/pt/prod/imes-icore/product-72794-829857.html; dental.formlabs.com/materials/#dental-model; dental.formlabs.com/materials/#dental-model; https://blissdentalartsandiego.com/services-list/all-on-x-teeth-in-one-day/.

Check product availability in your country

DIGITAL IMPRESSIONS

Specific transfer devices, called scanning JIGS, are used for intraoral scanning. These devices will later be converted into digital transfers, preventing the depth and amount of gingival tissue from interfering with the impression.

• Int J Oral Maxillofac Implants 2014;29(4):836-845
Accuracy of implant impressions for partially and completely edentulous patients: a systematic review.
Papaspyridakos P, Chen CJ, Gallucci GO, Doukoudakis A, Weber HP, Chronopoulos V.

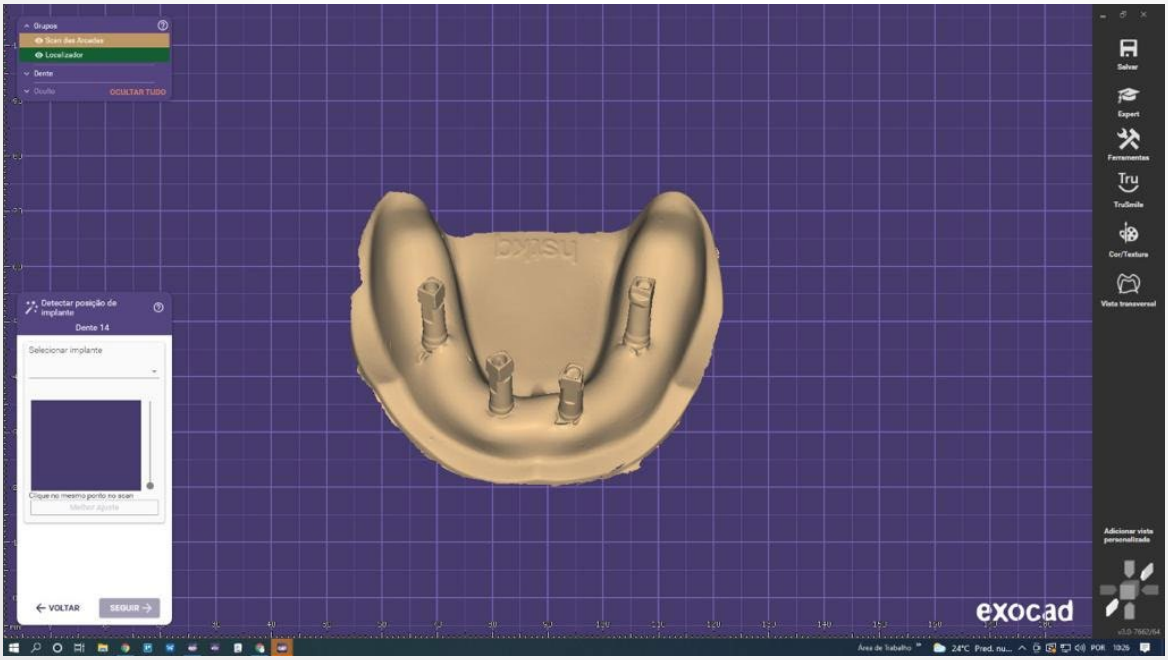

Escaneo digital

INTRAORAL SCANNER

Image capture is performed directly in the oral cavity. This eliminates clinical steps and avoids errors caused by distortions from impression materials and model fabrication.

This technique provides greater comfort for the patient, eliminating the need for a tray, impression materials, and gypsum models.

The intraoral scanner can be divided into two main units: the operational unit, which consists of the optical reader, and the processing control monitor, which guides the professional during image capture. Through the optical reader, light is incident on the patient's intraoral anatomical structures, which is reflected and detected by a sensor that is at a fixed distance and calculates the angle of reflection of the incident light beam through a process called triangulation.

• J Prosthet Dent. 2019 feb;121(2):246-251
Accuracy of digital technologies for the scanning of facial, skeletal, and intraoral tissues: a systematic review.
Bohner L, Gamba DD, Hanisch M, Marcio BS, Tortamano Neto P, Laganá DC, Sesma N.

• Bmc Oral Health. 2020; 20:263-284
Trueness of 12 intraoral scanners in the fullarch implant impression: a comparative in vitro study.
Mangano FG., Admakin O., Bonacina M., Lerner H., Rutkunas V., Mangano C.

Intraoral scanner

PROSTHETIC REHABILITATION

The provisional and definitive prostheses generated by the digital workflow can vary in terms of manufacturing types and materials.

Typically, they are milled using materials such as PMMA, zirconia, titanium, and others, or 3D printed using various types of resins specifically designed for use in dentistry.

- ***Precision and Accuracy of a Digital Impression Scanner in Full-Arch Implant Rehabilitation.***
Paolo Pesce, Francesco Pera, Paolo Setti, Maria Menini
Int J Prosthodont Mar/Apr 2018;31(2):171-175. doi: 10.11607/ijp.5535.

- ***Metal free, full arch, fixed prosthesis for edentulous mandible rehabilitation on four implants.***
Alfredo Passaretti 1 , Giulia Petroni 1 , Giovanna Miracolo 2 , Valeria Savoia 2 , Angelo Perpetuini 2 , Andrea Cicconetti 3
J Prosthodont Res 2018 Apr;62(2):264-267. doi: 10.1016/j.jpor.2017.10.002. Epub 2017 Dec 7.

- ***Retrospective 2- to 7-Year Follow-Up Study of 20 Double Full-Arch Implant-Supported Monolithic Zirconia Fixed Prostheses: Measurements and Recommendations for Optimal Design.***
Fernando Rojas Vizcaya
Prosthodont 2018 Jul;27(6):501-508. doi: 10.1111/jopr.12528. Epub 2016 Aug 29.

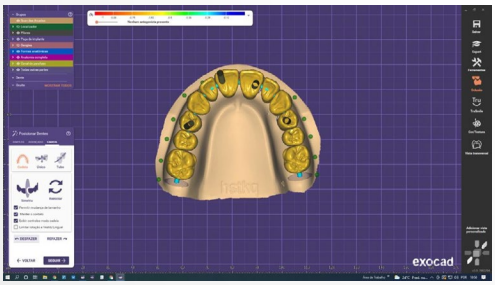

Digital planning

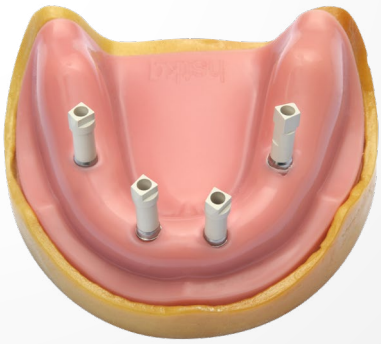

Model with Jigs

Milled prosthesis

Milled prosthesis installed

CONSIDERATIONS ON THE FULL ARCH CONCEPT

This concept is designed to make the most of the available bone and allow for immediate loading.

Points to consider when planning a full arch case:

- High primary stability
- Insertion torque: a minimum of 45 Ncm.
- If an insertion torque lower than this is recorded, we recommend a healing period before installing the provisional or definitive prosthesis.

If there are extraction sites, it is advisable to clean them before installing the implants.

It is advisable to place the implants between the post-extraction sockets.

To reduce cantilevers, tilt the posterior implants up to a maximum of 45°.

For tilted posterior implants, plan the screw access holes so that they are located in the occlusal plane of the first molar, second premolar, or first premolar.

SCIENTIFIC PUBLICATIONS

- Aires I, Berger J. Planning Implant Placement on 3D stereolithographic Models Applied with Immediate Loading of Implant-Supported Hybrid Prostheses After Multiple Extractions: A Case Series. Int J Oral Maxillofacial Implants. 2016; 31(1):172-178. doi: 10.11607/jomi.4186

- Bohner L, Gamba DD, Hanisch M, Marcio BS, Tortamano Neto P, Laganá DC, Sesma N. Accuracy of digital technologies for the scanning of facial, skeletal, and intraoral tissues: a systematic review.
  J Prosthet Dent. 2019 feb;121(2):246-251

- Bohner L, Gamba BB, Hanisch M, Marcio BS, Tortamano Neto P, Laganá DC, Sesma N. Comparison of conventional, photogrammetry, and intraoral scanning accuracy of completearch implant impression procedures evaluated with a coordinate measuring machine.
  Jprosthet Dent. 2021 mar;125(3):470-478

- Brånemark PI, Svensson B, van Steenberghe D. Ten-year survival rates of fixed prostheses on four or six implants ad modum Brånemark in full edentulism.
  Clin Oral Implants Res. 1995 Dec;6(4):227-31

- Carlos Aparicio, Carolina Manresa, Karen Francisco, Pedro Claros, Javier Al Andez, Oscar Gonzalez-Martin & Tomas Albrektsson. Zygomatic implants: indications, techniques and outcomes, and the Zygomatic Success Code.
  Periodontology 2000, Vol. 66, 2014, 41–58

- Chrcanovic BR, Albrektsson T, Wennerberg A. Survival and Complications of Zygomatic Implants: An Updated Systematic Review.
  J Oral Maxillofac Surg. 2016 Oct;74(10):1949-64.

- Duarte F, Ramos C, Silva JN. Immediate function with four zygomatic implants in patients with extreme maxillary atrophy – Case series.
  Journal of Surgery, Periodontology and Implant Research 2019; 1(2):51-55

- Graves S, Mahler BA, Javid B, Armellini D, Jensen OT. Maxillary all-on-four therapy using angled implants: a 16-month study of 1110 implants in 276 jaws.
  Dent Clin North Am 2011;55:779–794.

- Holtzclaw D. All-on-4® Implant Treatment: Common Pitfalls and Methods to Overcome Them.
  Compend Contin Educ Dent. 2016;37(7):458–465

- Holtzclaw D, Telles R. Pterygoid Fixated Arch Stabilization Technique (PFAST): A Retrospective Study of Pterygoid Dental Implants used for Immediately Loaded Full Arch Prosthetics.
  The Journal of Implant & Advanced Clinical Dentistry. 2018
  Dec;10(7):6-17

- Horita S, Sugiura T, Yamamoto K, Murakami K, Imai Y, Kirita T. Biomechanical analysis of immediately loaded implants according to the “Allon-Four” concept.
  J Prosthodont Res. 2017 Apr;61(2):123-132.

- Jensen OT, Adams MW. Secondary stabilization of maxillary m-4 treatment with unstable implants for immediate function: biomechanical considerations and report of 10 cases after 1 year in function.
  Int J Oral Maxillofac Implants. 2014,29(2):232-40.

- Lombardo G, D'Agostino A, Trevisiol L, Romanelli MG, Mascellaro A, Gomez-Lira M, Pardo A, Favero V, Nocini PF. Clinical, microbiologic and radiologic assessment of soft and hard tissues surroundingzygomatic implants: a retrospective study. Oral Surg Oral Med Oral Pathol Oral Radiol. 2016 Nov;122(5):537-546

- Ma B., Yue X., Sun Y., Peng L., Geng W. Accuracy of photogrammetry, intraoral scanning, and conventional impression techniques for complete-arch implant rehabilitation: an in vitro comparative study. Bmc Oral Health. 2021; 21:636-644

- Malchiodi L, Moro T, Cattina DP, Cucchi A, Ghensi P, Nocini PF. Implant rehabilitation of the edentulous jaws: Does tilting of posterior implants at an angle greater than 45 affect bone resorption and implant success?: A retrospective study. Clin Implant Dent Relat Res 2018 Oct;20(5):867-874

- Mangano FG., Admakin O., Bonacina M., Lerner H., Rutkunas V., Mangano C. Trueness of 12 intraoral scanners in the fullarch implant impression: a comparative in vitro study. Bmc Oral Health. 2020; 20:263-284

- Marcelo de Carvalho, Liliane Pacheco de Carvalho, Rogerio de Lima Romeiro, Carlos Eduardo Francischone, Bruno Salles Sotto-Maior, Fabio Bezerra. Nova Proposta Para Reabilitação de Maxila Atrófica: Implante Inclinado LONG. Int J Oral Maxillofac Implants 2016;31:1017–1022. (Portuguese Edition)

- Mattsson T, Köndell PA, Gynther GW, Fredholm U, Bolin A. Implant treatment without bone grafting in severely resorbed edentulous maxillae. J Oral Maxillofac Surg 1999; 57(3):281-287

- Maló P, de Araújo Nobre M, Lopes A, Moss SM, Molina GJ. A longitudinal study of the survival of Allon- 4 implants in the mandible with up to 10 years of follow-up. J Am Dent Assoc. 2011;142(3):310-20.

- Maló P, de Araújo Nobre M, Lopes A, Ferro A, Gravito I. All-on-4® Treatment Concept for the Rehabilitation of the Completely Edentulous Mandible: A 7-Year Clinical and 5-Year Radiographic Retrospective Case Series with Risk Assessment for Implant Failure and Marginal Bone Level. Clin Implant Dent Relat Res. 2015;17(2):531-41.

- Maló P., Rangert B., Nobre M. All-on-4 immediate-function concept with Brånemark System implants for completely edentulous maxillae: a 1-year retrospective clinical study. Clin Implant Dent Relat Res. 2005;7 Suppl 1:S88-94

- Martelli N, Serrano C, Van den Brink H, Pineau J, Prognon P, Borget.I. Advantages and disadvantages of 3-dimensional printing in surgery: A systematic review. Surgery. 2016 June; 159(6):1485-1500. doi: 10.1016/j.surg.2015.12.017.

- Meloni SM, De Riu G, Pisano M, Lolli FM, Deledda A, Guglielmo Campus G, et al. Implant Restoration of Edentulous Jaws with 3D Software Planning, Guided Surgery, Immediate Loading, and CAD-CAM Full Arch Frameworks. Int J Dent. 2013;2013:683423. doi: 10.1155/2013/683423.

- Padhye OV, Herekar M, Patil V, Mulani S, Sethi M, Fernandes A. Stress Distribution in Bone and Implants in Mandibular 6-Implant Supported Cantilevered Fixed Prosthesis: A 3D Finite Element Study Implant Dent. 2015 Dec;24(6):680-5.

- Patzelt SB, Bahat O, Reynolds MA, Strub JR. The all-on-four treatment concept: a systematic review.
  Clin Implant Dent Relat Res. 2014 Dec;16(6):836-55

- Peñarrocha M, Carrillo C, Boronat A, Balaguer J, Peñarrocha M. Palatal Positioning of Implants in Severely Resorbed Edentulous Maxillae.
  Int J Oral Maxillofac Implants 2009 May-Jun;24(3):527-33

- Papaspyridakos P, Chen CJ, Gallucci GO, Doukoudakis A, Weber HP, Chronopoulos V. Accuracy of implant impressions for partially and completely edentulous patients: a systematic review.
  Int J Oral Maxillofac Implants 2014;29(4):836-845

- Ozan O, Turkyilmaz I, Ersoy AE, McGlumphy EA, Rosenstiel SF. Clinical accuracy of 3 different types of computed tomography-derived stereolithographic surgical guides in implant placement.
  J Oral Maxillofac Surg. 2009 Feb;67(2):394-401. doi: 10.1016/j.joms.2008.09.033.

- Romanos GE, Nentwig GH. Immediate functional loading in the maxilla using implants with platform switching: five-year results.
  Int J Oral Maxillofac Implants 2009;24:1106–1112.

- Reiz SD, Neugebauer J, Karapetian VE, Ritter L. Cerec Meets Galileos - Integrated Implantology for Completely Virtual Implant Planning.
  Int J Comput Dent. 2014 17(2):145-157.

- Ujigawa K, Kato Y, Kizu Y, Tonogi M, Yamane GY. Three – dimensional finite elemental analysis of zygomatic implants in craniofacial structures.
  Int J Oral Maxillofac Surg. 2007 Jul;36(7):620-5

OUR GLOBAL PRESENCE

POINT YOUR PHONE'S CAMERA AT THE
QRCODE AND SEE WHERE S.I.N. IS PRESENT

HEADQUARTERS

2140 Vereador Abel Ferreira Av
Jardim Anália Franco
São Paulo – SP - Brazil

FACTORY

421 Soldado Ocimar Guimarães
da Silva St - Jardim Anália Franco
São Paulo – SP - Brazil

PORTUGAL BRANCH

General Ferreira Martins St, 10 8D -
1495-137 Algés - Portugal
+351 21 412-0336

sinimplantsystem.com

S.I.N.

Get to know Implantat, the educational streaming of S.I.N.

implantat.global

internacional@sinimplantsystem.com
www.sinimplantsystem.com

Visit our social networks

@sinimplantglobal

@sinimplantglobal

S.I.N. Implant System

/sin_implant